

Case Report

Juxta articular osteoid osteoma of the calcaneum: a rare case report

Gunjan Upadhyay*

Department of Orthopaedics Surgery, Calcutta Medical Research Institute, Kolkata, West Bengal, India

Received: 12 May 2020

Revised: 16 June 2020

Accepted: 30 June 2020

***Correspondence:**

Dr. Gunjan Upadhyay,

E-mail: gunjan453@gmail.com

Copyright: © the author(s), publisher and licensee Medip Academy. This is an open-access article distributed under the terms of the Creative Commons Attribution Non-Commercial License, which permits unrestricted non-commercial use, distribution, and reproduction in any medium, provided the original work is properly cited.

ABSTRACT

Osteoid osteoma of calcaneum in a juxta-articular position is a rare finding, it is most often misdiagnosed. It mimics arthritis. Osteoid osteoma is benign bone neoplasia mostly in male in 2nd - 3rd decade of life. It has typical features of night pain relieved with salicylates. 35 years old female present with right heel pain. Mother has positive history of rheumatoid arthritis. X-ray and computer tomography were done for diagnosis. Diagnosis was made of juxta-articular position of osteoid osteoma in the calcaneum. Lesion was excised after pre-anesthesia checkup and sent for histopathology. Once investigation was done diagnosis was made as an osteoid osteoma in juxta articular position of calcaneum. Treated by excision of the lesion surgically and specimen sent for biopsy which confirm osteoid osteoma.

Keywords: Osteoid osteoma, Juxta-articular position, Calcaneum, Arthritis, Heel pain

INTRODUCTION

Osteoid osteoma is a benign bone neoplasm with symptoms alike arthritis with more of male preponderance, in age group of 2nd - 3rd decade of life.¹

It is less than 1.5 cm in most cases.² Most common site of occurrence is femur followed by tibia. A specific feature is night pain, relieved by salicylates (NSAID). On X-ray findings, mostly located in diaphysis/metaphyseal (cortical/cancellous) area, with lytic radiolucent nidus as destructive pattern.

The tumour has a well-defined margin with intact corticomedullary delineation, intact cortex (thickened and sclerosed), homogenous matrix with narrow zone of transition, solid periosteal reaction and no soft tissue extension. Osteoid osteoma of calcaneum and in juxta-articular position is a rare finding.³ It is often misdiagnosed.

CASE REPORT

A 35-year-old female patient visited to our OPD because of pain in the heel (right) and difficulty in range of motion.

There was nil reported history of trauma. Mother of patient had positive history of rheumatoid arthritis.

Chief complaint

Pain localized to right heel, dull boring, aggravated with movement, relieved with rest and analgesics. Pain aggravated at night.⁶ Pain associated with mild swelling. No neurodeficit.

On examination

Patient had swelling and tenderness at the right heel with calf atrophy and heel not plantigrade. Tc 99 scan revealed more uptakes with a double-density sign of the right ankle during the metabolic phase (Figure 2). The computer

tomography (CT) and other observations were consistent with osteoid osteoma or osteoblastoma (Figure 3).⁸ However as size of nidus is less than 1.5 cm so it's likely osteoid osteoma only. The lady was operated after pre-anesthesia checkup (PAC) fitness and the lesion was excised completely under fluoroscopic guidance. The excised sample sent for histopathology and diagnosis was again confirmed by histopathological reports. The void space filled with bone grafts. The wound closed in layers and slab was applied with no weight bearing for 6 weeks.

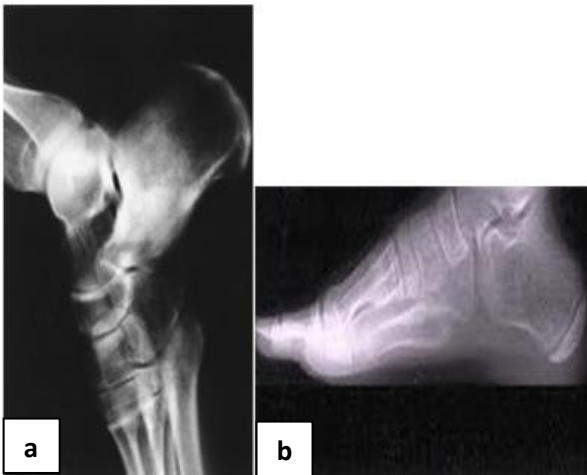


Figure 1 (a and b): X-ray of juxta articular osteoid osteoma.

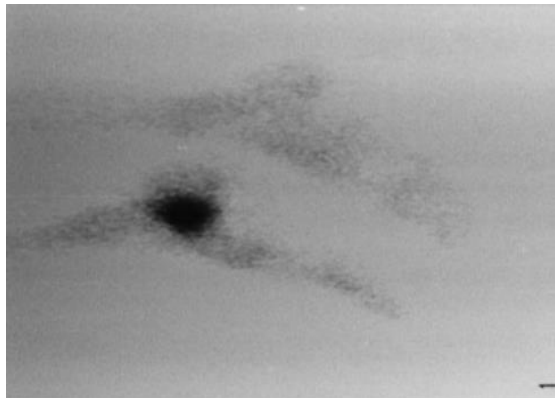


Figure 2: Bone scan pic of osteoid osteoma.

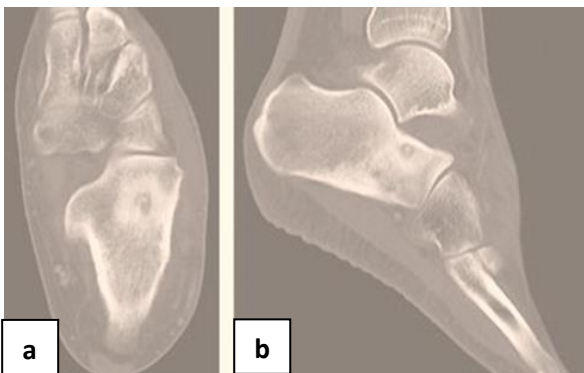

Figure 3 (a and b): Juxta articular osteoid osteoma.

Follow up

Suture removal done at 2 weeks. At 6 weeks with a check X-ray, patient allowed partial followed by complete weight bearing with no pain and full range of motion.

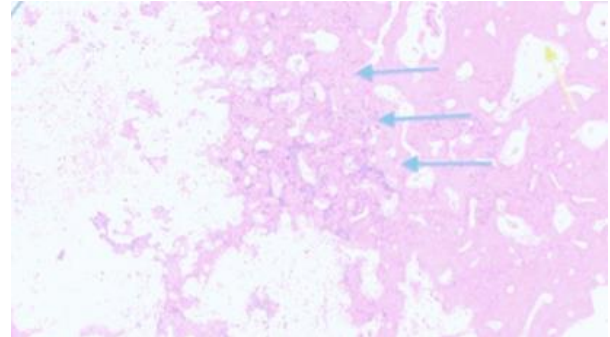


Figure 4: Juxta articular osteoid osteoma on histopathology.

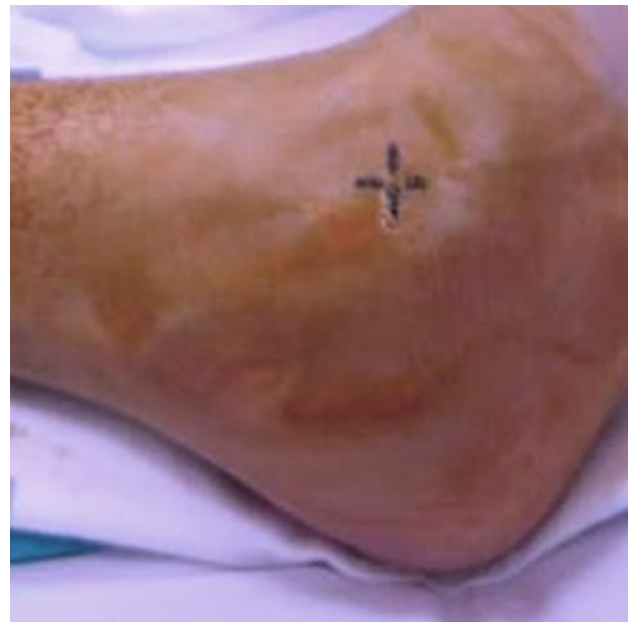

Figure 5: Clinical picture of osteoid osteoma.

DISCUSSION

Osteoid osteoma usually presents in the second to third decade with night pain relieved by analgesics. On X-ray sclerotic margin localized tumour in calcaneum.¹⁰ The diagnosis is often delayed due to late radiographic changes. Foot and ankle osteoid osteoma represent 6–15.6% of reported cases only. Osteoid osteoma of calcaneum is very rare. Juxta-articular osteoid osteomas in the ankle are frequently misdiagnosed because their symptoms may precede X-ray findings.

Differential diagnosis: Subtalar arthritis, Rheumatoid arthritis, ankle sprain etc. The use of plain tomograms, thin-section CTs and radionuclide scans helps in an early and correct diagnosis. A double-ring sign on scintigraphy

is characteristic of osteoid osteoma. Nonsurgical treatment with anti-inflammatory drugs and observation has been proposed recently. Radiofrequency ablation of osteoid osteoma is a promising alternative to surgery in selected patients.¹¹ If surgical intervention is necessary, en bloc resection is the procedure of choice. Preoperative CT is mandatory for appropriate planning of the surgical procedure.¹² Intraoperative fluoroscopy assists in localization and thorough excision of the lesion. The entire nidus must be removed to effect a cure.¹² Definite diagnosis is based on the macroscopic picture and histologic examination. The excised lesion appears as a dark brown or reddish nucleus surrounded by dense bone. Histopathologically, the central area consists of unorganized sheets of osteoid and bone cells. Suspicion of an osteoid osteoma should arise when young people present with subtalar pain that does not respond to the usual treatment. Subtle radiographic findings in patients with juxta articular lesions may lead to long delays in diagnosis and treatment. A double-ring sign in a bone scan is highly indicative of osteoid osteoma. MRI usually does not trace the tumor in the early stage. Thin-section CT sections of the calcaneum reveal (Figure 4) nidus of mature osteoid osteoma (haematoxylin and eosin stained; original magnification 100).¹⁴

CONCLUSION

Osteoid osteoma of calcaneum and in juxta articular position is a rare finding. It is often misdiagnosed. Once investigation like X-ray and CT Scan was done diagnosis was made as an osteoid osteoma. Treated by excision of the lesion surgically and specimen sent for biopsy which confirmed osteoid osteoma.

Funding: No funding sources

Conflict of interest: None declared

Ethical approval: Not required

REFERENCES

1. Temple HT, Scully SP. Tumors. In: Orthopaedic knowledge update: foot and ankle Rosemont (IL), Mizel MS, Miller RA, Sciolo MW, eds. American Academy of Orthopaedic Surgeons; 1998; 11-26.
2. Kransdorf MJ, Stull MA, Gilkey FW, Moser RP Jr. Osteoid osteoma. *Radiographics.* 1991;11:671-96.
3. Georgoulis AD, Soucacos PN, Beris AE, Xenakis TA. Osteoid osteoma in the differential diagnosis of persistent joint pain. *Knee Surg Sports Traumatol Arthrosc.* 1995;3:125-8.
4. Helms CA, Hattner RS, Vogler JB III. Osteoid osteoma: radionuclide diagnosis. *Radiology.* 1984;151:799-84.
5. Manes E, Francione V, Santucci A, Liberi A. Osteoid osteoma of the talus. *Ital J Orthop Traumatol.* 1990;16:191-201.
6. Potter WA Jr, Epstein EP. Osteoid osteoma of the os calcis: a case report. *J Am Podiatry Assoc.* 1972;62:435-7.
7. Piatkowski S, Warda E. Osteoid osteoma localized in the calcaneum. *Rev Chir Orthop Reparatrice Appar Mot.* 1973;59:609-13.
8. Mullin DM, Rodan BA, Bean WJ, Sehayik S, Sehayik R. Osteoid osteoma in unusual locations: detection and diagnosis. *South Med J.* 1986;79:1299-301.
9. Goranson K, Johnson RP. Osteoid osteoma of the os calcis: diagnosis is made by computerized tomography. *Orthop Rev.* 1986;15:98-102.
10. Jay RM. Surgical treatment of osteoid osteoma in an adolescent. *J Foot Surg.* 1990;29:495-8.
11. Khurana JS, Mayo-Smith W, Kattapuram SV. Subtalar arthralgia caused by juxtaarticular osteoid osteoma. *Clin Orthop.* 1990;252:205-8.
12. Biordsall PD. Osteoid osteoma: an unusual cause of foot pain. *Orthopedics.* 2001;24:173-4.
13. Khermosh O, Schujman E. Benign osteoblastoma of the calcaneus. *Clin Orthop.* 1977;127:197-9.
14. Casadei R, Ferraro A, Ferruzzi A, Biagini R, Ruggieri P. Bone tumors of the foot: epidemiology and diagnosis. *Chir Organi Mov.* 1991;76:47-62.
15. Rosenthal DI, Springfield DS, Gebhardt MC, Rosenberg AE, Mankin HJ. Osteoid osteoma: percutaneous radio-frequency ablation. *Radiology.* 1995;197:451-4.
16. Martinez S, Herzenberg JE, Apple JS. Computed tomography of the hindfoot. *Orthop Clin North Am.* 1985;16:481-96.

Cite this article as: Upadhyay G. Juxta articular osteoid osteoma of the calcaneum: a rare case report. *Int J Res Orthop* 2020;6:1109-11.