

Original Research Article

Retrograde intramedullary nailing for fractures of distal femur: a prospective study

Dileep K. S.*, Mahesha K

Department of Orthopaedics, K. S. Hegde Medical Academy, Deralakatte, Mangalore, Karnataka, India

Received: 06 October 2016

Accepted: 22 October 2016

***Correspondence:**

Dr. Dileep K. S

E-mail: dileepsri08@gmail.com

Copyright: © the author(s), publisher and licensee Medip Academy. This is an open-access article distributed under the terms of the Creative Commons Attribution Non-Commercial License, which permits unrestricted non-commercial use, distribution, and reproduction in any medium, provided the original work is properly cited.

ABSTRACT

Background: The objective of the present study was to evaluate the clinical and functional outcome of retrograde intramedullary interlocking nailing for fractures of distal femur.

Methods: This two-year prospective observational study includes all patients with fractures of distal femur who underwent retrograde intramedullary interlocking nailing. The patient was placed supine on fracture table with the affected limb flexed to 60°. Through a transpatellar approach, the nail was introduced in a retrograde method after serial reaming. Postoperatively knee range of motion was started immediately and weight-bearing was progressed after signs of fracture union were noted on x-rays. The outcome was evaluated for time taken for fracture union, complications and secondary procedures, knee range of motion and function at 1 year follow up using modified knee-rating scale of the hospital for special surgery.

Results: There were 21 patients who underwent retrograde intramedullary nailing for fractures of distal femur during the study period. According to AO/ASIF system, fractures were classified as A1 (n=15), A2 (n=3), and A3 (n=3). In 17 patients, fracture united without complications or secondary procedures. Fractures united at a mean time of 19.4 weeks. There were no varus or valgus malalignments but one patient had significant limb shortening. At the end of 1 year, excellent to good functional outcome was noted in 81% of patients.

Conclusions: Retrograde intramedullary nail fixation is a reliable method for treatment of fractures of distal femur. It promotes high rates of fracture union with minimal complications. This method does not interfere significantly with the knee function postoperatively.

Keywords: Distal femur fractures, Retrograde nailing, Union, Functional outcome

INTRODUCTION

Fractures of distal femur are common following road traffic accidents or fall from height in young or after trivial injury in elderly patients.¹ However, the appropriate method of management of these fractures is debatable. Plate osteosynthesis by conventional open reduction causes surgical trauma and impairs local vascularity. Less invasive stabilization system (LISS) also is associated with delay in union and nonunion and prolonged period of nonweightbearing.²

Intramedullary interlocking nailing is one of the standard procedures used to stabilize fractures of distal femur as it is a biologic method of fixation and load-sharing device allowing early weightbearing.³ Intramedullary nailing can be introduced either in an antegrade or a retrograde fashion for treatment of these fractures. Antegrade intramedullary nailing (AIMN) may lead to complications such as Trendelenburg gait or implant-related pain. Retrograde intramedullary nailing (RIMN) may cause complications including cartilage damage around

the intercondylar notch or patella and impaired knee function.

RIMN is preferred to antegrade nailing in patients with polytrauma, ipsilateral pelvic, acetabular, tibial or femoral neck fractures and hip dislocations, ipsilateral hip implants, obesity and pregnancy. The aim of the current study was to study the functional outcome of RIMN for fractures of distal femur.

METHODS

In this two-year prospective study, 21 patients who underwent retrograde interlocking nailing for fractures of distal femur in a tertiary care center were included. Informed written consent was taken from all patients. Institutional ethical clearance was obtained for this study. According to AO/ASIF system, fractures were classified as A1 (n=15), A2 (n=3), and A3 (n=3). Pathological fractures, periprosthetic fractures, associated ipsilateral patella fractures, ligamentous injuries of knee or neurovascular injuries, and fractures with open distal femoral physis were excluded from the study. The nails used for retrograde nailing had slots for two distal and two proximal screws. The patient was placed on a radiolucent table in supine position with the affected limb flexed at 60°. Transpatellar approach to the knee was obtained and the insertion point at the intercondylar notch anterior to Blumensaat's line along the femoral shaft axis was marked using image intensifier. Guide wire was passed through the proximal fragment after reduction and medullary canal was reamed in 0.5 mm increments until cortical contact appreciated. All fractures were reduced by closed methods. All fractures were statically locked.

Postoperatively, range of motion exercises were initiated in 2 days. Non weight-bearing mobilization was allowed immediately and gradually promoted to full weight-bearing as bridging callus was noted on x-rays at follow-ups. Patients were followed up at 6 weeks, 3 months, 6 months and 1 year. Patients were followed with x-rays and Modified Knee-Rating Scale of Hospital for special surgery for assessing the functional outcome.

The following parameters were noted in the proforma:

- Time taken for fracture union defined by radiography showing bridging callus on at least 3 cortices
- Secondary procedures performed
- Angular deformity as on anteroposterior and lateral radiographs, rotational deformity and leg-length discrepancies as measured clinically,
- Knee function as measured by modified knee-rating scale of the hospital for special surgery.

RESULTS

There were 15 males and 6 females aged from 24 to 77 years (mean 50 years) in the study. Right femur was involved in 14 subjects and left in 7. Road traffic accident

was the commonest mode of injury followed by fall from height and trivial injury as shown in Figure 1.

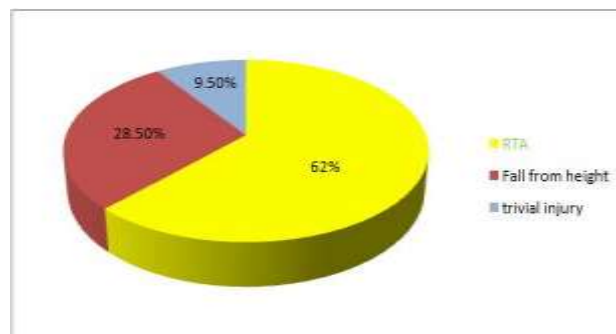


Figure 1: Mode of injury.

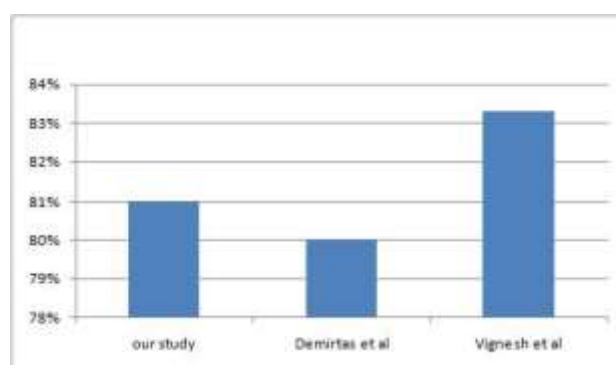


Figure 2: Functional outcome in our study, LISS¹¹ and dynamic condylar screw¹²

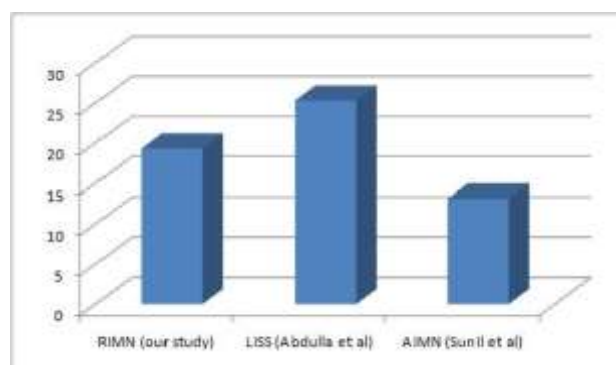


Figure 3: Time for fracture union (in weeks) in our study compared with LISS¹¹ and AIMN⁹.

One patient had ipsilateral tibial shaft fracture and two patients had upper limb bone fractures which required additional procedures either simultaneously or as a separate procedure. There were 18 closed and 3 open fractures. Average operative time was 1 hour 48 minutes (range 1 hour 25 minutes to 2 hours 10 minutes). Fracture union was noted in 17 patients without any secondary procedures or complications. Mean time for union was 19.4 weeks (SD 3.1 weeks). Of these, 3 patients underwent dynamization because of features of delayed union. All of these fractures united after dynamization. No patients developed nonunion. At the end of 1 year,

Modified Knee-Rating Scale showed 81% excellent to good scores for pain and function as given in Figure 2. There were no significant varus/valgus mal-alignments. Implant failure was noted in one patient and none of our patients had either superficial/ deep infections or fat embolism. Statistical analysis was done by descriptive method with percentages using SPSS version 17 software.

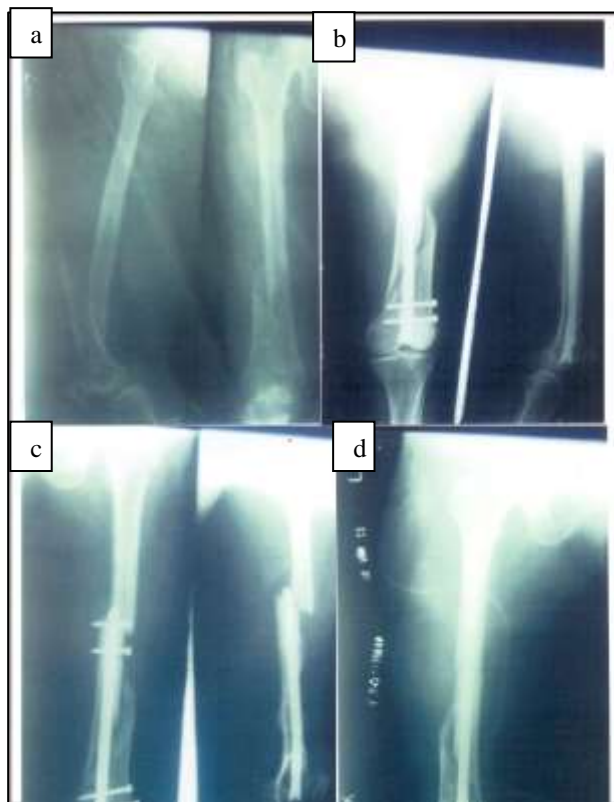

Figure4: a) Preoperative X-ray showing AO type A1 distal femur fracture; b) Postoperative X-ray showing fixation with RIMN; c) Stress fracture at the tip of the nail; d) Refixation done with long RIMN.

Table 1: Observations following RIMN for distal femur fractures.

Mean time for fracture union (closed fractures)	19.4 weeks (n=18)
Mean time for fracture union (open fractures)	21.3 weeks (n=3)
Varus/valgus mal-alignments	None
Knee range of movement	>110° (n=18) 91° -110° (n=2) <90° (n=1)
Shortening	> 1 cm (n=1)
Significant anterior knee pain	4

DISCUSSION

Fractures of the distal 9 cm of the femur are considered as the supracondylar fractures.⁴ They occur following

high-energy impact in young or low-energy injury in elderly osteoporotic bones. Intramedullary nailing and bridge plating are the frequently used treatment modalities for fractures of distal femur.^{3,5} They are biologic methods of fixation with less soft-tissue dissection and devitalization. As the fracture hematoma is preserved in these methods of fixation, complications such as nonunion and infection are less compared to traditional methods of open reduction and plating.² Compared to plating, intramedullary nails are load-sharing devices allowing early weight-bearing postoperatively.

Retrograde intramedullary nailing has many advantages over the antegrade method of fixation for these fractures. Polytrauma, ipsilateral pelvic, acetabular, tibial or femoral neck fractures and hip dislocations, ipsilateral hip implants, obesity and pregnancy are the clinical conditions where RIMN is preferred to AIMN.⁶⁻⁸ However, limitations of RIMN include interference with the knee function and longer union time in case of lower third femoral fractures.⁶

The average operating time in our study was 1 hour 48 minutes which was less than the time required for antegrade nailing of distal femur fractures.⁹ In our study, the mean time for bone union was 19.4 weeks for closed fractures which was more than the union time for antegrade nailing.⁹ This phenomenon has been attributed to fracture morphology, location of the fracture, soft tissue injury, or static locking of the nail.^{6,10} However, the mean time for fracture union was less than that for bridge plating which could be due to preservation of fracture hematoma and early postoperative weight bearing in retrograde nailing as shown in Figure 3.^{11,12} Average time taken for union in open fractures was 21.3 weeks which was comparable with the previous studies.¹³ In our study, 3 patients (14.3%) who had fractures at the middle-distal third junction had features of delayed union and underwent dynamization as a secondary procedure. Following dynamization, these fractures united uneventfully. This is comparable to the reports in the previous studies.¹¹ One complication which was noted in our study was the stress fracture at the tip of the nail. This could be due to the exaggerated anterolateral bowing of femur in osteoporotic bone which causes stress rising at the proximal fixation point. Knee pain, stiffness and function postoperatively have been the major concerns following RIMN. Various studies have shown that RIMN does not significantly affect the range of movement of the knee.^{6,14} In our study, 85.7% patients achieved >110o flexion at the end of 1 year follow-up. Modified knee-rating scale of Hospital for Special Surgery at the end of 1 year showed good to excellent results in 81% patients which are comparable to previously reported studies.^{6,11,13}

There are a few limitations of the study. The number of subjects involved in the study is less. Elderly patients are also included in the study; hence interpretation regarding knee function postoperatively may be difficult.

With increasing number of distal femur fractures, future research to develop minimally invasive treatment methods and early weight-bearing is suggested.

CONCLUSION

Retrograde intramedullary nail fixation is an effective method for treating fractures of distal femur. It provides a stable intramedullary fixation with less soft tissue injury. This method does not interfere significantly with the knee function postoperatively with negligible complications.

ACKNOWLEDGEMENTS

Authors would like to thank patients for their cooperation in the study.

Funding: No funding sources

Conflict of interest: None declared

Ethical approval: The study was approved by the institutional ethics committee

REFERENCES

1. Gurkan V, Orhun H, Doganay M, Salioglu F, Ercan T, Dursum M, et al. Retrograde intramedullary interlocking nailing in fractures of the distal femur. *Acta Orthop Traumatol Turc.* 2009;43:199-205.
2. Perren SM. Evolution of internal fixation of long bone fractures. The scientific basis of biological internal fixation: choosing a new balance between stability and biology. *J Bone Joint Surg Br* 2002;84:1093-110.
3. Heirholzer C, von Ruden C, Potzel T, Woltmann A, Buhren. Outcome analysis of retrograde nailing and less invasive stabilization system in distal femoral fractures. A retrospective analysis. *Indian J Orthop.* 2011;45:243-50.
4. Albert MJ. Supracondylar fractures of femur. *J Am Acad Orthop Surg.* 1997;5:163-71.
5. Krettek C, Muller M, Miclau T. Evolution of minimally invasive plate osteosynthesis (MIPO) in the femur. *Injury.* 2001;32(3):14-23.
6. Ostrum RF, Agarwal A, Lakatos R, Poka A. Prospective comparison of retrograde and antegrade femoral intramedullary nailing. *J Orthop Trauma.* 2000;14:496-501.
7. Anup K, Mehra MM. Retrograde femoral interlocking nailing in complex fractures. *J Orthop Surg (Hong Kong).* 2002;10:17-21.
8. Patterson BM, Routt ML Jr, Bernischke SK, Hansen ST Jr. Retrograde nailing of femoral shaft fractures. *J Trauma.* 1995;38:38-43.
9. Kulkarni SG, Varshneya A, Kulkarni GS, Kulkarni MG, Kulkarni VS, Kulkarni RM. Antegrade Interlocking nailing for distal femoral fractures. *J Ortho Surg.* 2012;20(1):48-54.
10. Moed BR, Watson JT. Retrograde intramedullary nailing, without reaming, of fractures of femoral shaft in multiply injured patients. *J Bone Joint Surg Am.* 1995;77:1520-7.
11. Demirta AS, Azboy I, Gem M, Alemdar C. Comparison of retrograde intramedullary nailing and bridge plating in the treatment of extra-articular fractures of distal femur. *Acta Orthop Traumatol Turc.* 2014;48(5):521-6.
12. Henderson CE, Lujan T, Bottlang M, Fitzpatrick DC, Madey SM, Marsh JL. Stabilization of distal femur fractures with intramedullary nails and locking plates: differences in callus formation. *Iowa Orthop J* 2010;30:61-8.
13. Surulivel VJ, Ganesan GR, Rajasekharan R. Dynamic condylar screw versus supracondylar nail in the management of supracondylar fracture distal femur. *Int Surg J.* 2015;2(3):373-6.
14. Tornetta P, Tiburzi D. Antegrade or retrograde femoral nailing. A prospective randomized trial. *J Bone Joint Surg Br.* 2000;82:652-4.

Cite this article as: Dileep KS, Mahesha K. Retrograde intramedullary nailing for fractures of distal femur: a prospective study. *Int J Res Orthop* 2016;2:276-9.