

Case Report

Joint preservation surgery: a priority to be thought of in selective hip osteoarthritis

Subramaian Kanthalu Narayanan, Rajesh Sellappan*

Department of Orthopaedics, Velammal Medical College Hospital and Research Institute, Madurai, Tamil Nadu, India

Received: 21 December 2019

Accepted: 31 January 2020

***Correspondence:**

Dr. Rajesh Sellappan,

E-mail: sellappanrajesh@gmail.com

Copyright: © the author(s), publisher and licensee Medip Academy. This is an open-access article distributed under the terms of the Creative Commons Attribution Non-Commercial License, which permits unrestricted non-commercial use, distribution, and reproduction in any medium, provided the original work is properly cited.

ABSTRACT

Femoroacetabular impingement (FAI) is one of the causes of hip arthritis. If FAI diagnosed earlier and treated properly, arthritis of hip and eventual total hip replacement (THR) can be potentially avoided. We report 48 yr male who presented with left hip severe pain, limp, restricted movements and unable do daily day activities. He is diagnosed to have pincer type of lesion in the acetabular rim and we did arthroscopic excision of the protruding fragment. The patient now has a pain free joint and able to squat and sit cross leg. His pre-operative oxford hip score was 30 which improved to 54.

Keywords: FAI, Arthroscopy, THR

INTRODUCTION

The concept of femoroacetabular impingement (FAI) has been recognized as a source of hip pain since the early 1990s.² The actual term was coined by Ganz et al in 2003.¹ Incongruity between the acetabulum, femoral head/neck junction can damage the labrum and cartilage of the joint which lead to arthritis. Two types of FAI are Cam type and Pincer type.¹

The first or cam impingement is caused by jamming of an abnormal femoral head with increasing radius into the acetabulum during forceful motion, especially flexion.^{3,4} The resulting shear forces produce outside-in abrasion of the acetabular cartilage and or its avulsion from the labrum and the subchondral bone in a rather constant anterosuperior rim area. Chondral avulsion in turn leads to tear or detachment of the principally uninvolved labrum.

The second or pincer impingement is the result of linear contact between the acetabular rim and the femoral head-

neck junction. The femoral head may have normal morphologic features and the abutment is the result of acetabular abnormality, often a general (coxa profunda) or local anterior over coverage (acetabular retroversion). The first structure to fail in this situation is the acetabular labrum. Continue impact of abutment results in degeneration of the labrum with intrasubstance ganglion formation, or ossification of the rim leading to additional deepening of the acetabulum and worsening of the over coverage. The persistent abutment, which often is anterior, with chronic leverage of the head in the acetabulum can result in chondral injury in the 'contrecoup' region of the posteroinferior acetabulum.³⁻⁵

CASE REPORT

Our patient is a 48 yr male came with severe left hip pain, limp, restricted movements and unable do daily day activities. He has tried all sorts of conservative management but his pain was worsening and his activities became restricted. On examination his range of movements was abduction 10*, adduction 10*, external

rotation 5°, internal rotation 0°. X-ray pelvis Ap view, CT and MRI scans were done.

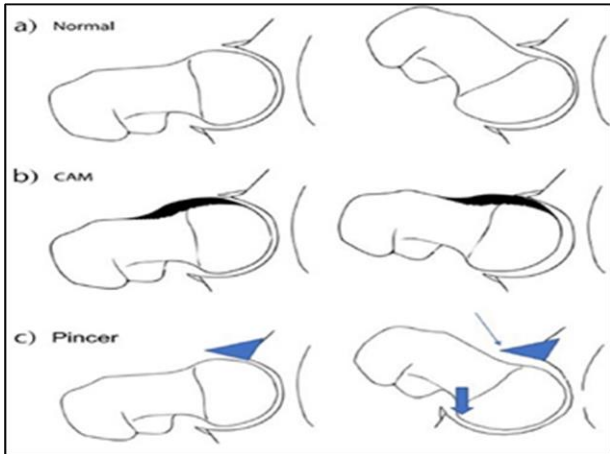


Figure 1: (a) Normal hip clearance, (b) cam type impingement with decreased head/neck offset; the cam enters the joint pushing the labrum aside and causing a shear injury to the chondrolabral junction, (c) pincer type impingement with excessive coverage of the acetabulum; crush injury of the labrum on the femoral neck (thin arrow) and contre-coup lesion (thick arrow).

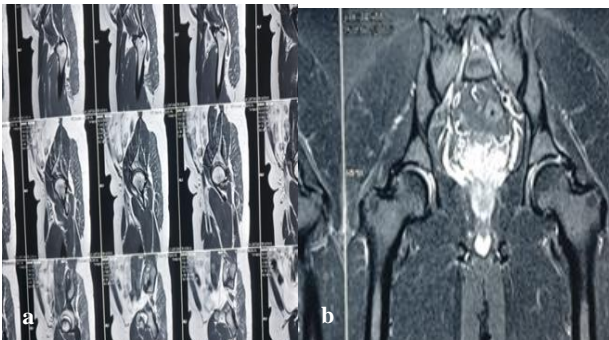


Figure 2 (a and b): Pre-operative pictures.

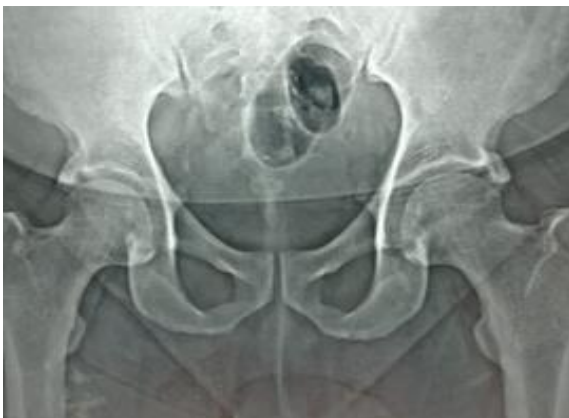

Figure 3: Post-operative picture I.

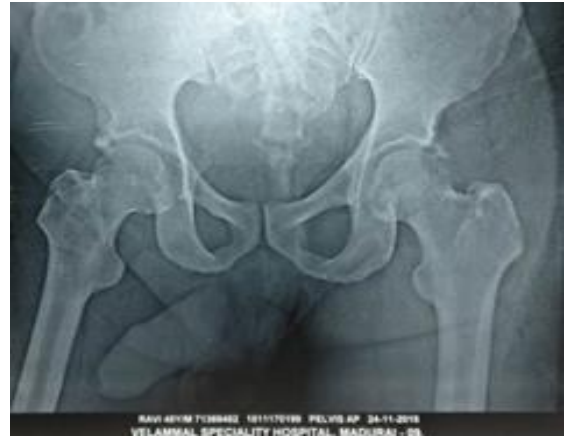

Figure 4: Post-operative picture II.

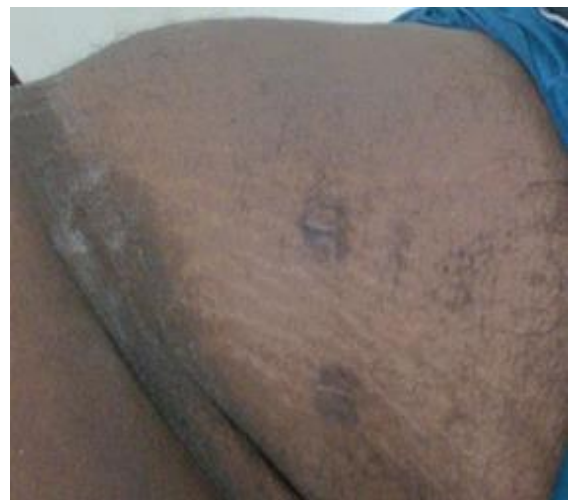

Figure 5: Healed scar.

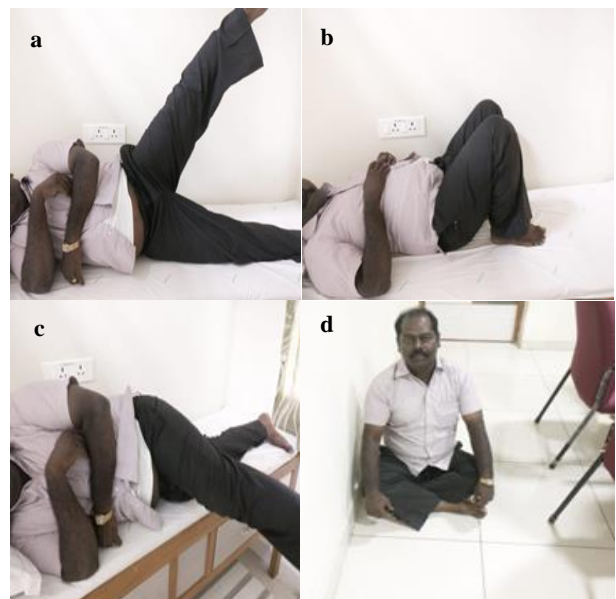

Figure 6 (a-d): Range of movements at 6 weeks.

He was operated under spinal anaesthesia in supine position with foot tied to fracture table boot, traction was given for access into the joint. Anterior and antro-lateral portals were used. Burr was used to remove the bony osteophyte which was causing the impingement and restricting the movements. Post-surgery patient was allowed full weight bearing and ROM exercise were started. Patient was comfortable after the surgery. He achieved near full range of movements within four weeks. His oxford hip score improved from 30 to 45. Patient was even able to squat and sit cross leg comfortably.

DISCUSSION

Hip arthroscopy has been around for decades, however this last decade has seen an exponential rise in the number of surgeries performed worldwide. FAI cases can be dealt adequately in a less invasive fashion. Hip arthroscopy has steep learning curve.⁶ Hip arthroscopy for FAI has been shown to provide excellent outcomes, with pain relief and return to sports or activities comparable with and even better than open treatment.

FAI is not only common in sports persons but also have severe symptoms in normal middle-aged persons, only thing is they are often under diagnosed. So proper evaluation and early intervention can give better outcome.

For successful results, planning and technique must be perfectly abided by anatomy and tissues respected. Not only radiographic evaluation of FAI is criteria for surgery, it is recommended that symptomatology and clinical tests is the integral part of the decision to operate. Not all patients with FAI need surgery and some deformities are not amenable to arthroscopic treatment. The prevalence of asymptomatic FAI was discussed in a review article by Frank et al.⁷ which highlighted the importance of associating clinical history and physical exam with radiological findings before deciding to treat the impingement. Patients with arthritis have been shown to have poorer outcomes after hip arthroscopy; therefore, hip arthroscopy is not advisable in patients with <2 mm of joint space in the weight-bearing area on an AP radiograph of the pelvis or Tönnis grade of 1 or greater.⁸ In summary, the current present indications for arthroscopic surgery in FAI are patients with a history and physical exam consistent with FAI, with radiographic evidence of focal impingement (cam, pincer or both, labral tears or chondrolabral disruptions) and minimal to no arthritic changes.

Hip arthroscopy has even been shown to have good outcomes with return to work in workers compensation cases. A recent study showed significantly improved patient-reported outcomes in patients aged <60 years who underwent hip arthroscopy for FAI when compared with a cohort that was waitlisted.⁹ Both groups had undergone three months of conservative treatment including

community physiotherapy before either having the arthroscopy or being waitlisted. In another study evaluating high-level athletes, return to their high-level sport after hip arthroscopy was measured as 3/4 by one year post-operatively.¹⁰ Multiple other articles have been published citing a high rate of return to sports in athletes and excellent pain relief after arthroscopic surgery for FAI.^{11,12}

CONCLUSION

In conclusion, we wish to highlight that FAI is not just a condition for sports person, it can also occur in normal middle-aged person. In middle aged population, it gets under diagnosed and hence they have substantial delay in treatment. We suggest to have high index of suspicion in patients coming with hip pain. Proper examination and patient selection help in better outcomes. Earlier intervention can avoid arthritis and eventually total hip replacement.

Funding: No funding sources

Conflict of interest: None declared

Ethical approval: Not required

REFERENCES

1. Ganz R, Parvizi J, Beck M, leunig M, Nötzli H, et al. Femoroacetabular impingement: a cause for osteoarthritis of the hip. *Clin Orthop Relat Res.* 2003;417:112-20.
2. Leunig M, Beaulé PE, Ganz R. The concept of femoroacetabular impingement: current status and future perspectives. *Clin Orthop Relat Res.* 2009;467:616-22.
3. Ito K, Minka MA, Leunig M, Werlen S, Ganz R. Femoroacetabular impingement and the cam-effect: An MRI based quantitative study of the femoral head-neck offset. *J Bone Joint Surge.* 2011;83B:171-6.
4. Nötzli HP, Wyss TF, Stoecklin C, Schmid MR, Treiber K, Hodler J. The contour of the femoral head/neck junction as a predictor for the risk of anterior impingement. *J Bone Joint Surge.* 2002;84:556-60.
5. Mella C, Villalón IE, núnñez Á, Paccot D, díaz-ledezma C. Hip arthroscopy and osteoarthritis: where are the limits and indications? *SICOT J.* 2015;1:27.
6. Nawabi DH, Mehta N, Chamberlin P, Hidaka C, Ge Y, Pan TJ, et al. Learning curve for hip arthroscopy steeper than expected. *J Hip Pres surge.* 2016;3(suppl_1):3-7.
7. Frank JM, Harris JD, Erickson BJ, Slikker W, Bush-Joseph CA, Salata MJ, et al. Prevalence of femoroacetabular impingement imaging findings in asymptomatic volunteers: a systematic review. *Arthroscopy.* 2015;31:1199-204.

8. Domb BG, Gui C, Lodhia P. How much arthritis is too much for hip arthroscopy: a systematic review. *Arthroscopy.* 2015;31:520-9.
9. Spencer-Gardner, Dissanayake R, Kalanie A, Singh P, O'Donnell J. Hip arthroscopy results in improved patient reported outcomes compared to non-operative management of waitlisted patients. *J Hip Preserve surge.* 2017;4:39-44.
10. Sansone M, Ahldén M, Jonasson P, Thomeé C, Swärd L, Baranto A, et al. Good results after hip arthroscopy for femoroacetabular impingement in top-level athletes. *Orthop J Sports Med.* 2015;3:23-5.
11. Philippon M, Schenker M, Briggs K, Koppersmith D. Femoroacetabular impingement in 45 professional athletes: associated pathologies and return to sport following arthroscopic decompression. *Knee surge Sports Traumatol Arthrosc.* 2007;15:908-14.
12. Casartelli NC, leunig M, Maffiuletti NA, Bizzini M. Return to sport after hip surgery for femoroacetabular impingement: a systematic review. *Br J Sports Med.* 2015;49:819-24.

Cite this article as: Narayanan SK, Sellappan R. Joint preservation surgery: a priority to be thought of in selective hip osteoarthritis. *Int J Res Orthop* 2020;6:404-7.