

Case Report

Shearing osteochondral humerus fragment fixed with bio-pins

Subramaian Kanthalu Narayanan, Rajesh Sellappan*, Dharmaraj

Department of Orthopaedics, Velammal Medical College Hospital and Research Institute, Madurai, Tamil Nadu, India

Received: 21 December 2019

Revised: 05 February 2020

Accepted: 05 February 2020

***Correspondence:**

Dr. Rajesh Sellappan,

E-mail: sellappanrajesh@gmail.com

Copyright: © the author(s), publisher and licensee Medip Academy. This is an open-access article distributed under the terms of the Creative Commons Attribution Non-Commercial License, which permits unrestricted non-commercial use, distribution, and reproduction in any medium, provided the original work is properly cited.

ABSTRACT

The fractures associated with an anterior dislocation generally reported in the literature have been Hill-Sachs lesions, avulsions of the greater tuberosity and glenoid fractures. Although literature presents many sequels of posterior shoulder subluxations, we have not come across any shearing type osteochondral fracture in the literature. In this case report we present a 24-year-old male following a fall from a motorcycle, sustaining a shearing type of osteochondral fracture likely from dislocation and relocation, which we fixed using absorbable biopins.

Keywords: Osteochondral fracture, Biopins, Posterior shoulder dislocation

INTRODUCTION

Osteochondral fractures of humeral head are very rare. The spectrum of the pathoanatomical findings after posterior shoulder subluxations or dislocations have already been described in the literature.¹⁻³ When a dislocation of the shoulder does occur, whether in an adult or child, the potential fractures most commonly associated with this injury are posterolateral compression fractures of the humeral head (Hill-Sachs lesions), greater tuberosity fractures, and glenoid rim fractures (bony Bankart).

Posterior glenohumeral dislocations represent only 2% of all shoulder dislocations, and their initial diagnosis is missed in more than 60% of cases.¹ Posterior shoulder dislocations result from axial loading of the adducted and internally rotated shoulder, violent muscle contractions resulting from seizures or electrocution, or a direct posterior force applied to the anterior shoulder.¹

CASE REPORT

A 24 years old male with right hand dominant came with history of fall from bike, he reported direct impact injury to his right shoulder. He was not sure of complete dislocation of his shoulder. He came with pain and complete restrictions of movements. We did a clinical and radiological investigation (X-ray and CT scan) which showed an osteochondral fragment displaced posteriorly.

We operated him under general anaesthesia in beach chair position. The deltopectoral approach was performed with maximum deltoid muscle preservation and tenotomy of the upper third of the subscapularis. The osteochondral fragment missing from the humeral head was “fished out” of the posterior-inferior axillary pouch. Osteochondral fragment measuring about 4×4 cms was anatomically reduced and initially stabilized with K-wire. Final stabilization done with 5 Bio-pins.

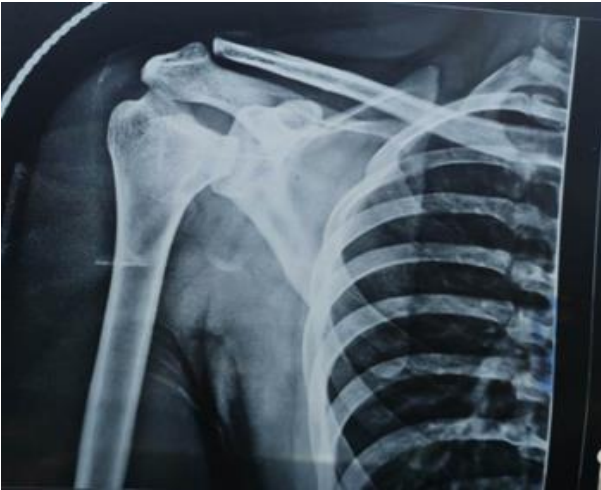

Figure 1: X-ray showing defect in humeral head.

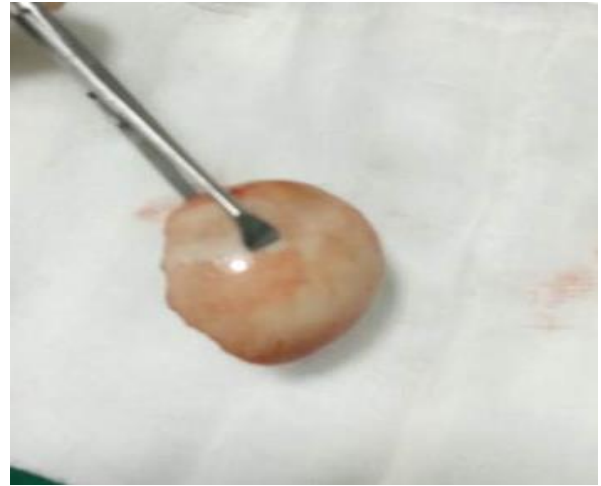


Figure 4: Osteochondral fragment.



Figure 2: Arthrex bio-pin.

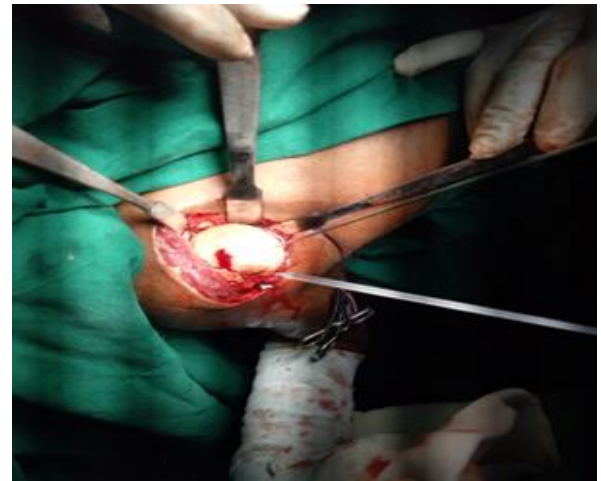

Figure 5: Bio-pin and fragment stabilized with K-wire.

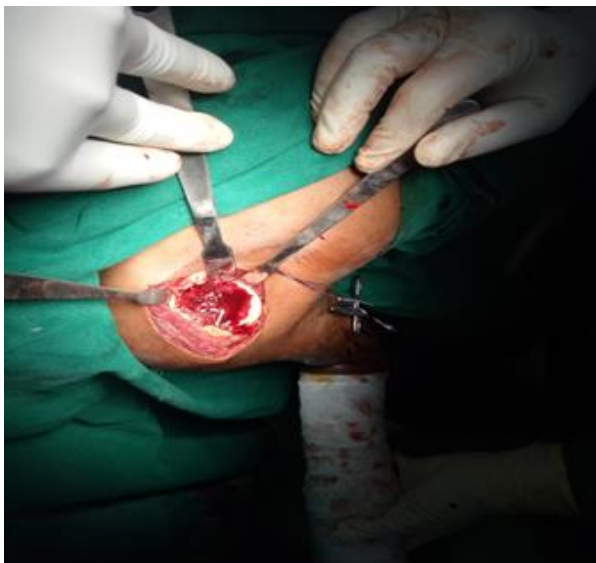

Figure 3: Osteochondral defect.

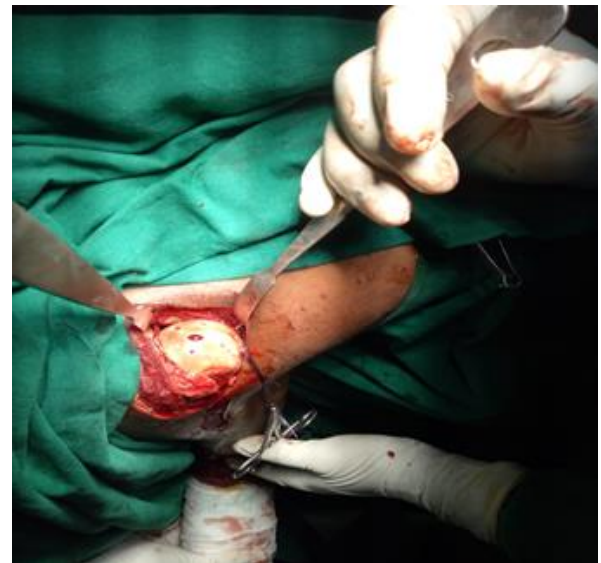

Figure 6: Fragment fixed with bio-pins.

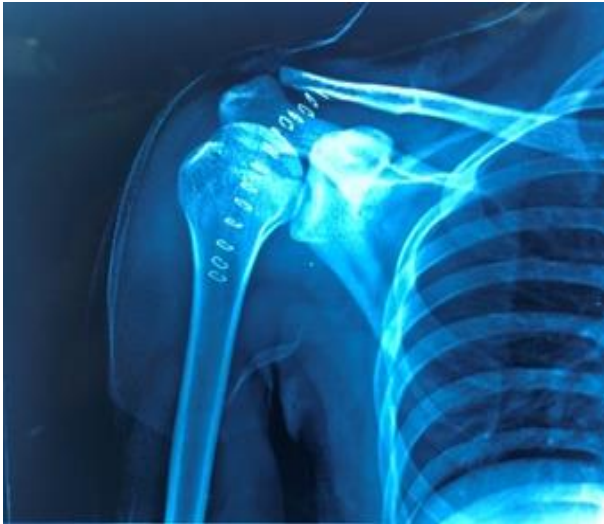

Figure 7: Immediate post-op.

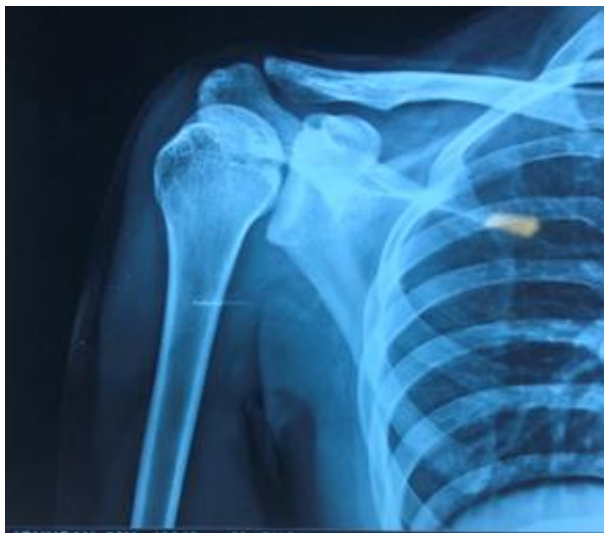

Figure 8: Six weeks post-op.

The subscapularis tendon was anatomically repaired. Postoperatively arm sling was given. Elbow and wrist movements started from day 1. Patient was discharged on 3rd postoperative day. Range of movement exercise was advice from 4th week.

DISCUSSION

Shearing osteochondral type fractures are very rare following trauma. Only few literatures have been published regarding shearing osteochondral fracture. These occurs mostly following dislocation and relocation. In the literature, lesions commonly associated with traumatic posterior subluxation/dislocation are the reverse Hill-Sachs or McLaughlin lesion.⁴ a posterior labral detachment, glenohumeral ligament lesions,¹ rotator cuff tears or posterior bony fractures.

Choi et al reported a shearing osteochondral fracture of the humeral head in a 12-year-old right-handed-dominant

boy injured while playing football following an anterior dislocation.⁵ The fracture was diagnosed by plain radiographs and MRI. This patient was treated conservatively with good results.

Fandridis et al reported a similar type of shearing type osteochondral fracture of 26 years old male following a fall from the two wheelers. The fracture was fixed with Herbert screw.

Humeral head shearing fractures of a smaller size can be fixed with Herbert screws if they are eccentric. But if the fracture fragment is large then the screw length may not be adequate enough to hold on the opposite cortex. As our patient had a large fragment, we decided to use alternate mode of fixation. The other form fixations available currently are bio-screws or threaded pins, but again these come with a fixed length and may not hold on the opposite cortex. So, our plan was to use a Bio-pins which comes in a length of 110 mm and that can be adjusted to the length as per the requirement. We used all these pins in five places to have a good compressive hold of the fragment so that early mobilization can be started. The bio pins are originally described for the osteochondral fragments of the knee joint, but the indications can be extended in such kind of situation.

CONCLUSION

To the best of our knowledge, our patient represents the first reported case of an osteochondral shearing fracture of the humeral head fixed with absorbable Bio-pins.

Funding: No funding sources

Conflict of interest: None declared

Ethical approval: Not required

REFERENCES

1. Rouleau DM, Hebert-Davies J. Incidence of associated injury in posterior shoulder dislocation: Systematic review of the literature. J Orthop Trauma. 2012;26:246-51.
2. Abrams JS. Arthroscopic repair of posterior instability and reverse humeral glenohumeral ligament avulsion lesions. Orthop Clin North Am. 2003;34:475-83.
3. Ames JB, Millett PJ. Combined posterior osseous Bankart lesion and posterior humeral avulsion of the glenohumeral ligaments: A case report and pathoanatomic subtyping of “floating” posterior inferior glenohumeral ligament lesions. J Bone Joint Surge Am. 2011;93:118.
4. McLaughlin HL. Posterior dislocation of the shoulder. J Bone Joint Surge Am. 1952;24:584-90.
5. Choi YS, Potter HG, Scher DM. A shearing osteochondral fracture of the humeral head following an anterior shoulder dislocation in a child. HSS J. 2005;1:100-2.

6. Hovelius BL, Sweden G. Anterior dislocation of the shoulder in teen-agers and young adults. *J Bone Joint Surge Am.* 1987;69:393-9.
7. Hovelius L. The natural history of primary anterior dislocation of the shoulder in the young. *J Orthop Sci.* 1999;4:307-17.

Cite this article as: Narayanan SK, Sellappan R, Dharmaraj. Shearing osteochondral humerus fragment fixed with bio-pins. *Int J Res Orthop* 2020;6:423-6.