

## Original Research Article

# Primary intra-articular osteotomy for varus malunion of the medial condyle of the tibial plateau

Jeremy Bliss, Dan Barnabas Inja\*, Manasseh Nithyananth, Vinoo Mathew Cherian

Department of Orthopedics, Christian Medical College, Vellore, Tamil Nadu, India

**Received:** 16 December 2019

**Revised:** 13 January 2020

**Accepted:** 14 January 2020

**\*Correspondence:**

Dr. Dan Barnabas Inja,

E-mail: [injadan@yahoo.com](mailto:injadan@yahoo.com)

**Copyright:** © the author(s), publisher and licensee Medip Academy. This is an open-access article distributed under the terms of the Creative Commons Attribution Non-Commercial License, which permits unrestricted non-commercial use, distribution, and reproduction in any medium, provided the original work is properly cited.

### ABSTRACT

**Background:** Reconstructive operative procedures for post-traumatic deformities of the tibial plateau have been described in literature, though rarely. We report short term follow-up of eleven such cases of primary intra-articular osteotomy.

**Methods:** From 2005 through 2011, a primary intra-articular osteotomy for varus malunion of the medial condyle of the tibial plateau was performed in eleven consecutive cases. The patients were assessed clinically and radiologically at a minimum of 28 months post-operatively. The functional outcome was assessed using Rasmussen score. Paired 't' test was used to determine the statistical significance.

**Results:** There were eleven male patients. Average follow up was 59 months (range 28 to 159). Articular congruity was restored to acceptable in all patients and varus malalignment was corrected from a mean of 1.5 degrees varus to 5.7 degrees of valgus (statistically significant, two-tailed P value of 0.0056) to an extent comparable to the normal side (mean 5.8 degrees). There were no infections. All patients had good to excellent functional outcome.

**Conclusions:** A primary intra-articular osteotomy and osteosynthesis for malunited medial condyle fracture of the tibial plateau would help to restore mechanical alignment and improve functional outcome.

**Keywords:** Varus malunion, Intra-articular osteotomy, Medial tibial plateau

### INTRODUCTION

Mechanical malalignment, primary cartilage damage and posttraumatic joint incongruity contribute to the development of posttraumatic osteoarthritis. The prevalence of posttraumatic osteoarthritis of the knee joint at the time of long-term follow-up after tibial plateau fractures has been estimated to be 30%.<sup>1</sup> Correction of posttraumatic deformities is a treatment option to control the progression of symptoms from those deformities. Correction of joint incongruity is also an important factor in reducing secondary arthrosis. Correction of posttraumatic valgus deformity of the proximal part of the tibia without an intra-articular zone of depression has been reported to be achieved with a proximal varus osteotomy to correct the valgus and

restore natural alignment.<sup>2</sup> Reconstructive procedures involving preservation of the native knee joint are rarely mentioned in the literature.<sup>3</sup> Primary osteotomy and osteosynthesis for varus malunion of the medial condyle fracture of the tibia have been rarely reported in literature. The aim of this study was to analyze results of the primary osteotomy and osteosynthesis for varus malunion of the medial condyle fracture of the tibia.

### METHODS

This is a retrospective study, done at a tertiary care centre in South India (Unit-1, Department of Orthopaedics, Christian Medical College, Vellore, Tamilnadu, India). From January 2005 through December 2010 fourteen consecutive patients underwent primary osteotomy and

osteosynthesis for varus malunion of the medial condyle fracture of the tibia. Twelve patients were self-referred to our clinic for pain/deformity and instability while the other two were on follow-up as they had undergone the primary operation at our clinic.

Three patients had to be excluded as adequate follow up was not available and attempts to contact them were not fruitful. All patients were male with a mean age of forty-four years (range twenty-nine to sixty-six years). The right knee was involved in five patients while the left knee was involved in six patients. Prior to the secondary operation, six patients had primary operative treatment of which, four were operated elsewhere, two were operated in our clinic and the remaining five patients had undergone some form of immobilization from elsewhere. There were five patients who, at the time of sustaining medial condyle tibia fracture, had other serious injuries. One patient's knee involvement was part of poly trauma, one had an ipsilateral Hoffa's fracture, one had an ipsilateral and a contralateral tibia fracture, one had an ipsilateral open tibia fracture, one had a contra lateral femur fracture. One patient had an iatrogenic common peroneal nerve palsy after upper tibial pin application at his local hospital. The mean time period between injury/primary operation and osteotomy was six months (range 2 to 13 months). Preoperative pain was not graded with any system. Two surgeons had performed the operations over a period of six years. The evaluation was done by the principal author who joined as a new faculty and did not play a role in the treatment of any of these patients. Those patients who were from outside the country sent back a clinician completed proforma.

### **Pre-operative work up**

Radiographic assessment was done for both knees in standing position including the lower half of the femur and the upper half of the tibia. CT scan or an MRI was done in those patients suspected to have a complex injury. The medial proximal tibial angle (medial proximal tibial angle of 90 degrees is considered as 0 degrees. Tilt towards varus is considered negative and tilt towards valgus is considered positive) was calculated on a weight bearing anteroposterior X-ray. The institutions licensed and routinely used GE Centricity web PACS3 system, which is universally available at all work-related computers was used for measuring the angles. Statistical analysis was done using the Social Science Statistics available free online (paired T test and Chi square test) (at the URL <http://www.socscistatistics.com/tests/Default.aspx>).

### **Operative technique**

All the surgeries were performed by the same team of surgeons. A medial parapatellar approach was used for the medial condyle of the tibia. Primary osteotomy of the malunited medial condyle was performed starting from distal medial and going proximal lateral towards the

intercondylar area, fracture surfaces were freshened and medial condyle was elevated. The correction was hinged around the intercondylar area, and all patients had tricortical iliac crest grafting. Osteosynthesis was performed with a medial buttress plate under direct vision and image intensifier control, checking both in the antero-posterior and lateral views for correction of varus and the posterior slope. Wound closure was done in layers over a suction drain. All patients received standard parenteral antibiotic prophylaxis for 48 hours. Immediate post-op weight bearing was not allowed. Patients were put on a posterior slab for 14 days, till suture removal, during which only passive short arc movements were done and active knee mobilization was started after suture removal.

### **RESULTS**

There were eleven patients, all were males with a mean age of 43.27 (range: 29-66). The average time from injury to index surgery in this institution was 6.4 months (range: 2-13). Among them 5 patients had right sided injury the rest were left. Mean follow up was 53.9 months (range: 24-124). The pre-operative tibio femoral valgus alignment of -1 (range: -9 to 5) degrees was corrected to a mean of 5.6 (range: -2 to 12) degrees and was comparable to the normal side which was 5.7 (range: 2 to 9) degrees. The pre-operative medial proximal tibial angle of a mean of -13.1 degrees (range: -24 to -6) was corrected to a mean of -4.4 degrees (range: -17 to 0) and was comparable to the normal side which was -2.2 degrees (range: -5 to 0). None had a significant intraarticular step.

There were 4 patients who had fixed flexion deformity (range: 5-10 degree) and 5 with a lag, which reduced to 1 (with 5 degrees) and none respectively at final follow up. The mean range of movement from preoperative to final follow up improved from 104 degrees to 118 degrees, paired samples t-test was performed for the same showing a significant p value of 0.010608.

**Table 1: Characteristics of the patients.**

S.no	Age (yrs)	Sex	Side	Gap*	Follow up†
1	37	M	R	5	28
2	59	M	L	5	120
3	66	M	R	13	74
4	40	M	R	10	26
5	29	M	L	8	24
6	49	M	L	2	28
7	49	M	L	6	64
8	34	M	L	2.5	159
9	35	M	L	3	26
10	44	M	R	3	63
11	34	M	R	13	45

M: Male, R: Right, L: Left, Gap\*: Duration in months between the injury and surgical intervention at our centre, †: Maximum available follow up in months.

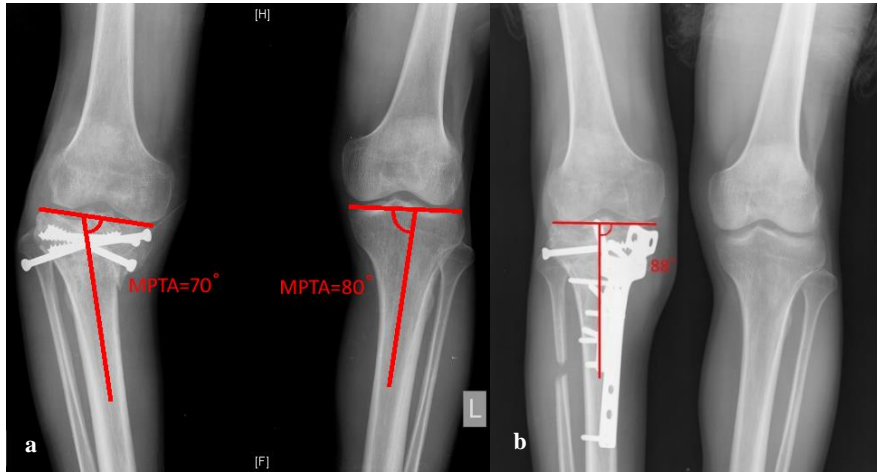


Figure 1: (a) Pre-op radiograph with deformity measured, (b) post-op radiograph showing correction.

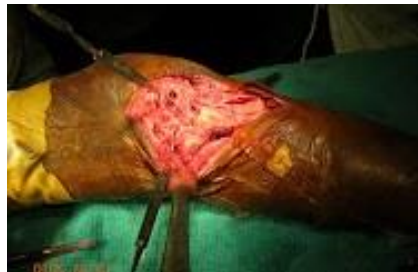

Figure 2: Intra-op image of exposure.

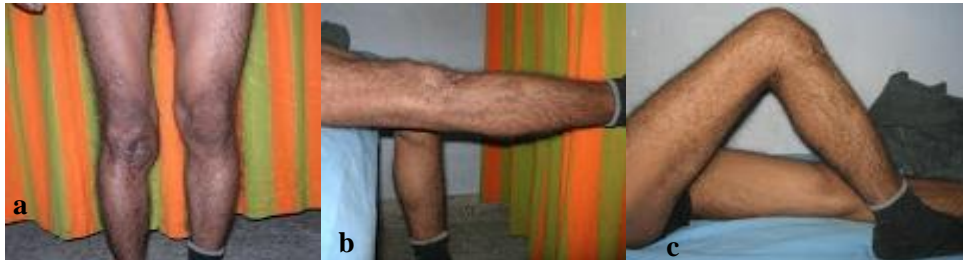

Figure 3 (a-c): Post-op knee alignment and range of movement.

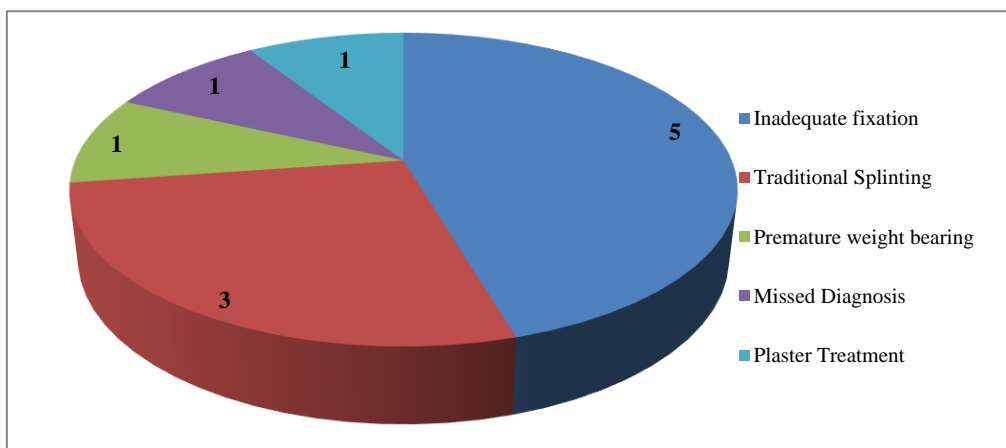
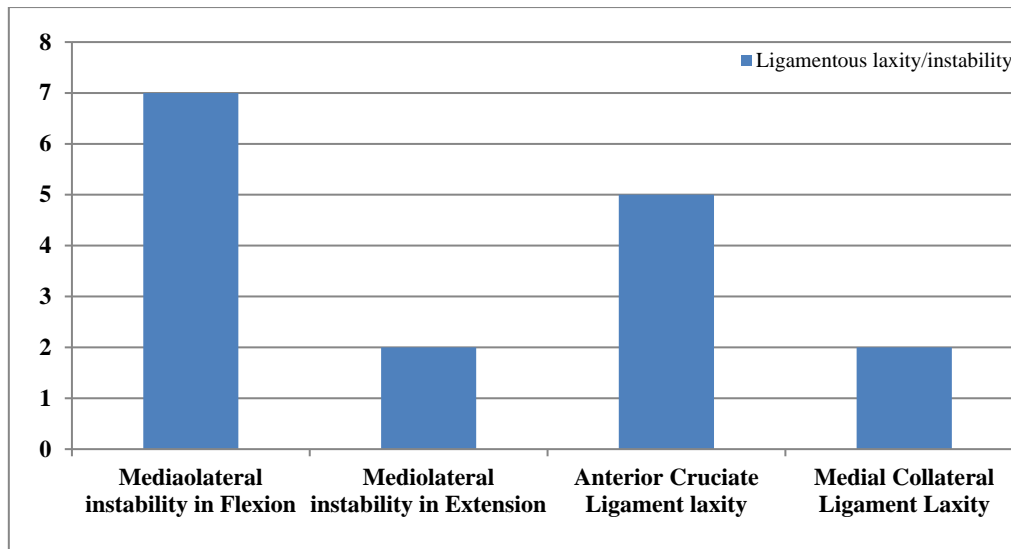


Figure 4: Suspected reasons for malunion.



**Figure 5: Final follow-up laxity/instability.**

At final follow up six patients had a Rasmussen score which was excellent and five had good functional outcome. None of the patients had infection. At final follow up, the radiological parameters and Rasmussen score had improved in all patients (Figures 1-5).

## DISCUSSION

In this short-term follow-up study, reconstruction of a depressed and varus malunion of a medial tibial condyle fracture in a small group of severely disabled patients yielded good to excellent results. Literature pertaining to upper tibial metaphyseal osteotomy is available against which we are compelled to discuss our results. In our study there was subjective improvement in pain and instability. As with all osteotomies, potential hazards include overcorrection or under correction of the varus deformity, which may compromise the functional result.<sup>5</sup> In our study there was no overcorrection. There was no infection in our series. This infection rate is lower than that reported in studies of total knee arthroplasties in patients with a prior tibial plateau fracture.<sup>6</sup> There was statistically significant correction obtained in the tibio-femoral alignment and was comparable to the unaffected side. This would lead to significant reduction in uneven joint loading and thereby reduce the rate of degeneration as is the phenomenon which occurs in a varus knee which has undergone corrective osteotomy.<sup>7,8</sup> Obvious advantages of the reconstructive osteotomy are maintenance of the native knee joint with a good functional outcome.<sup>9</sup> Follow up is necessary to evaluate long term outcome as Rinonapoli describes that results tend to deteriorate after fifteen years.<sup>10</sup> Though osteotomies are described for degenerative and post gonococcal arthritis, they have been done extra articularly and have shown good outcome at follow up.<sup>11,12</sup> There is a high incidence of anterior cruciate and medial collateral ligament laxity which did not significantly reduce the functional outcome. Satisfactory outcome has been

reported in combined primary intraarticular and extraarticular osteotomy for valgus malunion of tibial plateau. Sundaram et al do mention that sustained pain relief provided by osteotomy is not known.<sup>12</sup> The number of patients with flexion deformity and lag reduced considerably. There was improvement in the range of movement, though marginal probably due to a better mechanical alignment of the quadriceps mechanism. More importantly, none lost their pre-operative range of movement.

Primary osteotomy in these patients addresses the deformity at the site of its occurrence. The intraarticular osteotomy also decreases the width of the widened tibial plateau which would not have been addressed by a secondary (metaphyseal) osteotomy.<sup>9</sup> Open as well as closed wedge osteotomies also give good results.<sup>13</sup> Follow up is necessary to evaluate long term outcome as Rinonapoli describes that results tend to deteriorate after fifteen years.<sup>10</sup>

## CONCLUSION

A primary intra-articular osteotomy and osteosynthesis for the malunited medial condyle fracture of the tibial plateau would help to restore mechanical alignment and improve functional outcome. This osteotomy addresses the deformity at the site of its occurrence. It is important to bear in mind that patients with multiple injuries could be having a medial condyle fracture of the tibia which could be missed. Inadequate fixation, treatments with indigenous methods of splinting and medial condyle fracture being a less serious entity in the patient with multiple injuries are leading causes for a patient presenting with a malunion of the medial condyle of tibia. Long term follow-up is desirable to evaluate outcomes such as late collapse and secondary osteoarthritic changes.

## ACKNOWLEDGEMENTS

The authors wish to acknowledge the work of Dr. Alfred Cyril Roy who conceptualized and designed this study.

*Funding: No funding sources*

*Conflict of interest: None declared*

*Ethical approval: Not required*

## REFERENCES

1. Rademakers MV, Kerkhoffs GM, Sierevelt IN, Raaymakers EL, Marti RK. Operative treatment of 109 tibial plateau fractures: five- to 27-year follow-up results. *J Orthop Trauma*. 2007;21:5-10. Erratum in: *J Orthop Trauma*. 2007;21:218.
2. Marti RK, Verhagen RA, Kerkhoffs GM, Moojen TM. Proximal tibial varus osteotomy. Indications, technique, and five to twenty-one-year results. *J Bone Joint Surg Am*. 2001;83:164-70.
3. Weiss NG, Parvizi J, Trousdale RT, Bryce RD, Lewallen DG. Total knee arthroplasty in patients with a prior fracture of the tibial plateau. *J Bone Joint Surg Am*. 2003;85:218-21.
4. Rasmussen PS, Gothenburg. Tibial Condylar Fractures Impairment Of Knee Joint Stability As An Indication For Surgical Treatment. *JBJS*. 1973;55:7.
5. Sprenger TR, Doerzbacher JF. Tibial osteotomy for the treatment of varus gonarthrosis. Survival and failure analysis to twenty-two years. *J Bone Joint Surg Am*. 2003;85:469-74.
6. Saleh KJ, Sherman P, Katkin P, Windsor R, Haas S, Laskin R, et al. Total knee arthroplasty after open reduction and internal fixation of fractures of the tibial plateau: a minimum five-year follow-up study. *J Bone Joint Surg Am*. 2001;83:1144-8.
7. Goutallier D, Van S, Driessche SV, Manicom O, Ali ES, Bernageau J, et al. Influence of lower-limb torsion on long-term outcomes of tibial valgus osteotomy for medial compartment knee osteoarthritis. *J Bone Joint Surg Br*. 2006;88:2439-47.
8. Maquet PV. Valgus osteotomy for osteoarthritis of the knee. *Clin Orthop Relat Res*. 1976;120:143-8.
9. Kerkhoffs GMMJ, Rademakers MV, Altena M, Marti RK. Combined Intra-Articular and Varus Opening Wedge Osteotomy for Lateral Depression and Valgus Malunion of the Proximal Part of the Tibia. *J Bone Joint Surg Am*. 2008;90:1252-7.
10. Emanuele R, Giovanni MB, Antonella C, Salvatore M. Tibial Osteotomy for Varus Gonarthrosis: A 10- to 21-Year Followup Study. *Clin Orthop Rel Res*. 1998;353:185-93.
11. Douglas N, Robert B, Cecil HR, Timothy BJ. Survivorship of the High Tibial Valgus Osteotomy A 10-to 22-Year Follow up Study. *Clin Orthop Rel Res*. 1999;367:18-27.
12. Sundaram NA, Hallett JP, Sullivan MF. Dome osteotomy of the tibia for osteoarthritis of the knee. *J Bone Joint Surg Br*. 1986;68(5):782-6.
13. Tuli SM, Kapoor V. High tibial closing wedge osteotomy for medial compartment osteoarthritis of knee. *Indian J Orthop*. 2008;42(1):73-7.

**Cite this article as:** Bliss J, Inja DB, Nithyananth M, Cherian VM. Primary intra-articular osteotomy for varus malunion of the medial condyle of the tibial plateau. *Int J Res Orthop* 2020;6:360-4.