

## Original Research Article

# A clinical study of surgical management of paediatric humeral supracondylar fracture

Ajay Kumar<sup>1</sup>, Karthik Padmanabhan<sup>2\*</sup>

<sup>1</sup>Department of Orthopaedics, College of Medicine and JNM Hospital, Kalyani, West Bengal, India

<sup>2</sup>Department of Orthopaedics, Deepak Hospital, Jayanagar, Bangalore, Karnataka, India

**Received:** 09 August 2019

**Revised:** 26 August 2019

**Accepted:** 03 September 2019

### \*Correspondence:

Dr. Karthik Padmanabhan,

E-mail: [naveennumeroduos@gmail.com](mailto:naveennumeroduos@gmail.com)

**Copyright:** © the author(s), publisher and licensee Medip Academy. This is an open-access article distributed under the terms of the Creative Commons Attribution Non-Commercial License, which permits unrestricted non-commercial use, distribution, and reproduction in any medium, provided the original work is properly cited.

## ABSTRACT

**Background:** Injury to the supracondylar region of the humerus and complete displacement of the fragments occurs in many of the cases when children usually fall while playing. This is most common fracture seen in children, makes up to 60% of all elbow injuries. Early intervention results in excellent reduction and avoids complications. Concomitant vascular and nerve damages may occur. Open reduction and internal fixation is a helpful option for the treatment of supracondylar fracture of humerus in children.

**Methods:** Forty children who presented with displaced supracondylar fracture of the humerus were treated with open reduction and internal fixation with Kirschner (K) wires after thorough pre-operative investigation during the course of the study. Children below the age of 13 were selected irrespective of the sex.

**Results:** Good results were obtained in 60% of the patients, fair in 30% and poor in 10%. The poor results were due to the open fracture and in two cases the patient presented very late to the hospital. Complications such as nerve injuries, vascular injuries, infections were noticed in the study. Four patients had cubitus varus and twelve patients had flexion loss on follow-up study.

**Conclusions:** Open reduction and internal fixation with K wire is an easy, simple, inexpensive method, which has good outcome.

**Keywords:** Supracondylar fracture, Fracture humerus, Open reduction, Internal fixation, K wire

## INTRODUCTION

Sir Robert Jones had echoed the opinion of 20<sup>th</sup> century about elbow injuries as 'the difficulties experienced by surgeons in making an accurate diagnosis; the facility with serious blunders can be made in prognosis and treatment; and the fear shared by so many of the subsequent limitation of function, serve to render injuries in the neighbourhood of the elbow, less attractive than they might otherwise have proved'. These concerns hold true even today. The presentation of a child with a swollen, injured elbow brings anxiety not only to the parents but also to the treating surgeon.

Supracondylar fractures of humerus are the most common elbow injury in children and makes up approximately 60% of all elbow injuries.<sup>1</sup> However it becomes increasingly more uncommon as the child approaches adolescence. The average age group of patients is at the age of 7 years.

Supracondylar fracture is the fracture, which involves the lower end of the humerus usually involving the thin portion of humerus through olecranon fossa, or just above the fossa or through metaphysis. Considering, the number of patients injured and the severity of the initial injury that occurs, great diligence is required to secure an

excellent result and to avoid or minimize the crippling complications, such as Volkmann's ischaemic contracture, myositis ossification, stiffness, permanent nerve injuries and malunion.

Though it is general belief that accurate reduction is not required to achieve a good result as growth may correct a deformity and functional end results of malalignment are usually good, however cosmetic end results are very poor. Stiffness of the elbow which sometimes follows relatively minor injuries plus remarkable sensitivity of the injured joint add to the difficulties of treatment and prognosis. Recurrence of displacement may occur despite accurate closed reduction and immobilization in flexion. The injuries of elbow can sustain vascular damage and nerve injury more frequently than in any other limb injuries.<sup>2</sup>

No controversy persists regarding management of undisplaced or partially displaced fractures of the supracondylar region. However in treatment of a completely displaced fracture not one but many exist. While others have devised blind pinning after reduction or pinning under X-ray control, some advocate to the extent of accepting an unsatisfactory closed reduction and perform an osteotomy, at a later stage to correct the deformity. In the region of elbow, however, there is often more indication for aggressive treatment, including operative management.

Hence, this study was undertaken to study the outcome of surgical management of supracondylar fracture in children.

## METHODS

The present clinical study comprising of 40 cases which had completely displaced supracondylar fractures of the humerus were studied at College of Medicine and JNM Hospital, Kalyani, West Bengal. The study was conducted consisting of children up to the age thirteen years during the period January 2018 to June 2019 for duration of 18 months. This clinical study of surgical management of supracondylar fracture of humerus in children was conducted to evaluate the causes of failed closed reduction, to study the complications associated with the fracture, to evaluate the results of supracondylar fractures treated by open reduction and internal fixation with criss-cross or 2 lateral Kirschner (K) wires and to evaluate the outcome and post-operative complications associated. A detailed history of the mode of injury was obtained from the parents as well as patient. Routine blood investigations and urine examination were done on admission. Tetanus prophylaxis and antibiotics were given preoperatively. Average range of period from injury to surgery was 24-36 hours.

### Operative procedure

Open reduction and internal fixation with criss-cross or two lateral K wires. General anesthesia was administered

in all cases and patient was operated in prone position. A posterior longitudinal incision was taken in the lower third of the arm extending up to the olecranon. In 12 cases, triceps-splitting approach was adopted and in the remaining 8 tongue shaped incision was made in the triceps reflecting it proximally. Fracture site was exposed and haematoma if present was evacuated. Fracture was reduced by levering the distal fragment anterior. Reduction was assessed by taking into consideration the pillar anatomy. The medial and lateral pillars were palpated to ascertain the reduction in the triceps splitting approach, and were visualized in the tongue shaped incision approach. Perfect anatomical realignment of the pillars was difficult to achieve due to its comminution. Exploration for ulnar nerve was not done. Elbow was held in reduced position and a 1.5 mm K-wire mounted over a hand drill was passed from the medial epicondyle region obliquely across the fracture site to engage the opposite cortex. In a similar manner, another 1.5mm K-wire was passed from the lateral epicondyle obliquely across the fracture site to engage the opposite cortex. Fracture stability was assessed and K-wires were bent and cut. Wound was closed in layers and sterile dressing applied. Tourniquet was released. Above elbow posterior POP slab was applied. K-wires were placed in the coronal plane, the wires travel up each SC column, with wide separation at the fracture site.

Mitchell and Adam (1961) have proposed the criteria for evaluation of the end results of supracondylar fractures.<sup>3</sup>

*Good:* Change in the carrying angle less than 5 degrees or limitation of elbow motion less than 10 degrees.

*Fair:* Change in the carrying angle from 5-15 degrees or limitation of elbow motion 10 to 20 degrees.

*Poor:* Change in the carrying angle more than 20 degrees or limitation of elbow motion more than 20 degrees.

### Post-operative management

Limb elevation was given. Antibiotics and analgesics were given. A check X-ray was taken on the 2<sup>nd</sup> day. The patient was discharged and advised to do active finger movements. Patients were called back on the 10<sup>th</sup> day in the out-patient department and the sutures were removed. Above elbow POP slab was reapplied for three weeks.

### Follow up

Patients were called four weeks following surgery. The POP slab was removed. Clinical evaluation was done to rule out distal neurological deficient. After removal of POP slab, check X-ray was taken to see whether union had taken place or not. Most of the patients had union at about four weeks. The K-wires were removed in the out-patient department. Arm sling was given for one week. Patients were advised active elbow movements after demonstrating it to the patient. A specific mention and

warning was given after removal of the slab, about avoiding oil massage and passive stretching exercises which is a favourite method of treatment advocated by the village bone setters.

They were advised to come once in four weeks to assess the range of the elbow movements. They were then called at three months following surgery. X-ray was taken, the range of elbow movements and carrying angle were assessed. Patients who were having neurological involvement were followed up every week following surgery. Later follow-ups were made at end of 6 months. The range of movements and presence of deformities were measured by using a goniometer at predetermined intervals.

**Ethical issue**

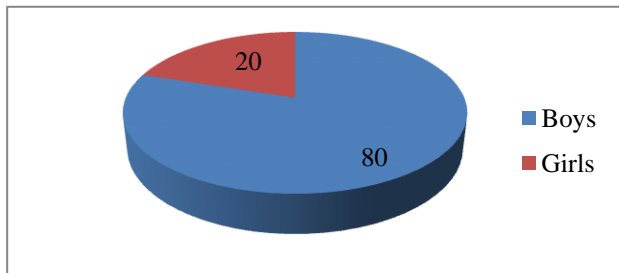
This study started after the clearance from ethical committee of College of Medicine and JNM Hospital. All the operative procedures followed were standard procedures. The participants were explained in detail about the study. Written informed consent was taken from the participants or guardians before enrolment.

**Statistical analysis**

The data collected was entered in MS Excel 2016. The data was analyzed by IBM SPSS version 22.0 (licensed). Proportions were calculated.

**RESULTS**

In the present study, there were 32 (80%) boys and 8 (20%) girls (Figure 1). The mean age of presentation was 8.2 years.



**Figure 1: Sex distribution.**

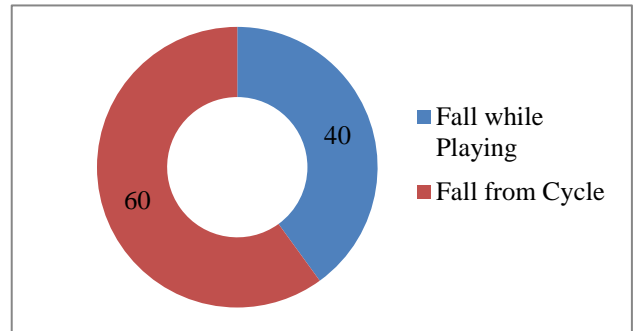
28 (70%) patients presented with involvement of left side and 12 (30%) patients on the right side (Table 1).

**Table 1: Side involvement.**

Left elbow	Right elbow	Total
28	12	40

Out of the 40 cases, 16 (40%) sustained fracture due to a fall while playing and the remaining 24 (60%) patients

due to fall from cycle most often the cases fall was on an outstretched hand (Figure 2).



**Figure 2: Cause of injury.**

All patients presented with pain, swelling, “S” shaped deformity of the lower arm and inability to move the affected elbow. On examination all patients had diffuse swelling all around the elbow. Puckering of the skin was noted at the site of fracture in 8 cases. All patients had shortening of the arm as compared to the normal side (Table 2). The average period from injury to presentation was 8 hours. 6 cases gave history of having received massage from osteopath.

**Table 2: Clinical features.**

Clinical features	No. of patients (%)
Pain	100
Swelling	100
Deformity	100
Inability to move	100
Puckering of skin	20
Arm shortening	100

Included median nerve injury (6 in number) and two (5%) cases of radial nerve injury. These were traumatic neuropraxias which recovered completely in 10-12 weeks. In 6 (15%) patients, the radial pulse was feeble, but the patients were able to move his fingers feeble and the character of the pulse became normal after open reduction and internal fixation with K wires (Table 3).

**Table 3: Associated injuries.**

Associated injuries	No. of patients (%)	
Nerve injury (neuropraxia)	Median nerve	15
	Radial nerve	5
	Ulnar nerve	0
Vascular Injury	Radial	15
	Ulnar	0

Four (10%) patients suffered from open fracture (type 1). X-ray of the elbow was taken in 2 planes antero-posterior and lateral. 40 cases of Gartland’s Grade III type of supracondylar fractures were included in this series and

these were further grouped into fractures with postero-medial, postero-lateral and posterior displacement.

Out of these 40 cases, 12 (30%) had postero-medial, 22 (55%) has postero-lateral, 4 (10%) had posterior displacement and 2 (5%) cases were of flexion type (Table 4 and 5).

**Table 4: Type of displaced fractures.**

Extension type	Flexion type	Total
38	2	40

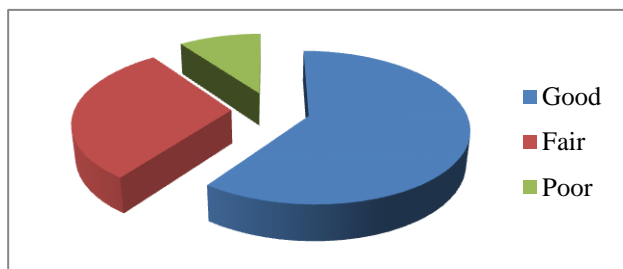
**Table 5: Type of displacement.**

Postero-medial	Postero-lateral	Posterior
12	22	4

Out of 40 cases, 10 (25%) were given one trial and 4 (10%) cases were given two trials of closed reduction under sedation, taking care to maintain good radial artery pulsation. In 8 (20%) cases, the radial artery pulsation had to be restored by open reduction and internal fixation. Check X-ray of the 3 patients who underwent closed reduction was taken. They proved unsatisfactory and were admitted for open reduction and internal fixation because there was no re-establishment of shaft condylar angle to at least 20 degrees, there was rotation in the horizontal plane (crescent sign), inability to restore the radial pulse by closed reduction and irreducibility secondary to soft tissue interposition i.e., periosteum and capsule.

Remaining 26 (65%) cases were taken up for primary open reduction and internal fixation because of extensive separation of the fracture fragments, being open fractures or risk of severe vascular compromise even at the slightest attempt of manipulation.

In our series, 24 cases (60%) exhibited good results, 12 cases (30%) exhibited fair results and remaining 4 cases (10%) exhibited poor results (Figure 3). 4 cases had poor results, which are considered as failures. All 4 cases had a limitation of elbow movement of more than 20 degrees flexion, and cubitus varus of 20 degrees, associated with medical pillar comminution, out of which 2 were open fractures and 2 presented late to the hospital.



**Figure 3: End results of supracondylar fracture treatment.**

## DISCUSSION

Supracondylar fractures of the humerus in children are common injuries and complete displacement of the fragments occurs in many of the cases. In our study mean age of the study group was 8.2 years and were in the age group between 2 and 13 years which was a tad higher compared to other studies. In the compared studies, Andrew study had 6.6 years (age group 2-13 years), Ambrosia study had 7 years (age group 4-10 years), Fowles et al study had 7.2 years (age group 5-10 years) and study by Kurer et al had 8 years average age (age group 5-12 years).<sup>4,7</sup>

Male to female ratio in our study was 4:1 which was comparable to Fowles et al study.<sup>7</sup> However, female children were comparatively more in Ambrosia study (81:19).<sup>5</sup>

Type of fracture was comparable to other series. In the study by Fowles et al, type of fracture was 90% of extension type (ET) and 10% of flexion type (FT), Flynn et al study had 95% ET and 5% Ft compared to ours which has 95% ET and 5% FT.<sup>6,8</sup> Open fractures in our study comprised 10% of total SC fractures comparable to Fowles et al study (6.4).<sup>6</sup>

In our study, incidence of radial nerve (4 times) and median nerve (6 times) injuries were higher than in other series. Boyd et al study had 2.4% incidence of radial nerve injury, 1.5% had median nerve injury and ulnar injury incidence was 0.5%.<sup>1</sup> Fowles et al study had 2.7% incidence each of radial and median nerve injuries and 0.9% of ulnar nerve injury.<sup>6</sup> In our study, though there was no incidence of ulnar nerve injury, radial (5%) and median (15%) nerve injuries were higher.

Vascular complications are greatly preventable to an extent. However, cubitus varus deformity seems to be the most common complication with any of the methods of treatment.

In a study by Mitchell et al, 38 of the 83 patients had a varus deformity following treatment.<sup>3</sup> 60% of those of the above 38 who showed a varus deformity were treated by manipulative reduction and immobilization and 18% of those 38 patients who were treated by Dunlop's traction exhibited such a deformity.

The average change in the carrying angle was greater, in the group that was treated by manipulation and immobilization only.

In the present series all the patients have been followed up for a period of one year. Six patients were in addition subjected to local massage by an osteopath according to their history, but clinic-radiologically showed no evidence of myositis ossificans. The considerable soft tissue oedema is an expression of the underlying injury and its severity, and it indicates a regional vascular

compromise. Immediate exploration in these cases achieves good soft tissue decompression, allows case of reduction, and as a result of anatomic restoration of the span of soft tissue, the progression of oedema was arrested.

Flexion type of SC fractures is much less common than the extension types, with a reported frequency ranging from less than 1% to 10% of SC fractures. It must be remembered that the posterior periosteum is torn, and the anterior periosteum now functions, as a tension band by extending the arm. Having the elbow extended is awkward and it does not control the proximal migration of the fracture. Open reduction and pinning is therefore recommended for displaced flexion type of SC fractures.

2 cases of flexion type displaced fracture encountered were treated by open reduction and internal fixation with K wires. No complications were encountered in this age.

The pulse had returned immediately after open reduction when feeble radial pulse in three cases was encountered

before reduction. 6 cases of median nerve and 2 cases of radial nerve involvement were noted pre operatively which were transient and recovered spontaneously over the period of 10-12 weeks. Pin tract wound irritation was seen in 4 of the cases, which presented as points of hyper granulation tissue could have probably been avoided by burying the K wires subcutaneously. 4 cases had superficial wound infections, which subsided immediately after appropriate antibiotic cover. These minor complications however had no influence whatsoever on the final functional results. No case of secondary nerve lesion of Volkmann’s ischemia or myositis ossificans was seen.

The single most important factor that decides the overall prognosis in a given patient is the extent of pillar comminution. Pillar comminution was seen in 10 cases on exploration. Perfect anatomic realignment of the pillars then becomes difficult in such situations we suggest first, the anatomic restoration and stabilization of the pillar that is not comminuted, followed by that comminuted pillar.

**Table 6: Comparison of occurrence of cubitus varus and decreased range of motion with other modalities of treatment.**

Treatment	Authors	No. of fractures	Length of follow up	Patients with varus deformity (%)	Patient with decreased range of motion (%)
<b>Overhead skeletal traction</b>	Smith (1960) <sup>9</sup>	10	6 months	10	40
<b>Dunlop’s traction</b>	Mitchell et al <sup>3</sup>	16	10 years	18	19
<b>Closed reduction and immobilization</b>	Mitchell et al <sup>3</sup>	42	10 years	60	94
<b>Closed reduction and percutaneous pinning</b>	Fowles et al <sup>6</sup>	23	2 years	36	23
<b>Open reduction and internal fixation</b>	Gruber et al (1964) <sup>10</sup>	23	1-5 years	0	27
	Sandegard (1943) <sup>11</sup>	31	1-15 years	53	91
	Ramsey et al (1973) <sup>12</sup>	54	3 months–4 years	20	0
	Kurer et al (1990) <sup>7</sup>	52	1 year	32	24
	Present study	40	6 months–1 year	10	30

The restoration of the olecranon fossa anatomy is an index of the anatomy of the overall restoration. The elbow is then passively extended, and one can compare the resultant carrying angle interpretively. We retain the implants for six weeks, follow up the patient radiologically, and decide on implant removal when there is evidence of reunion. In 4 cases we have accepted fixation in varus position. This was necessary in order to achieve a stable reduction, which was possible only in varus position and was attributed to the degree of pillar comminution. All the poor results in this series are associated with medical pillar comminution (Table 6).

The overall results at the end of one year were good in 60% of cases, fair in 30%, and were poor in 10% of cases. This evaluation thus takes into account strictly the

resultant change in the carrying angle, when it comes to classifying the results, despite the good range of elbow movement at the end of one year. The K wires are introduced through the epicondylar region and the wires must lie in the same coronal plane. In 10 cases, two parallel lateral K wires are passed from the lateral epicondyle obliquely across the fracture site to engage the opposite cortex. Our study results when compared to other studies had lesser incidence of poor results of 10% compared to Holmberg (1945) study of 56% (good), 28% (fair) and 16% (poor); Gruber et al study of 65.3% (good), 13% (fair) and 21.7% (poor); Kurer et al study of 62.9% (good), 21.2% (fair) and 15.9% (poor).<sup>7,10,13</sup>

In none of the patients there was a neuro-vascular complication as against the possibility of such a complication in methods employing percutaneous



pinning.<sup>8</sup> From the economic standpoint, all our patients were discharged from the hospital on an average after four days. The patient turnover is thus rapid unlike in those protocols or treatment where overhead traction or Dunlop traction is advocated.

The results of our study compared well with the results observed by other authors in literature. These results are better than equivalent results in series describing the closed methods of treatment, both for the change of carrying angle is concerned as well as the motion of the elbow is considered.

## CONCLUSION

Open reduction of displaced supracondylar fractures in children is based on the principles of treatment of intra-articular fractures namely, anatomic restoration, stable internal fixation, and early mobilization. The underlying philosophy encompasses the mechanical understanding of the distal end of the humerus and should be applied to displaced fractures wherein accurate alignment of the fracture ends is difficult to maintain and rotational malunion may jeopardize the end results. Open reduction provides an accurate, stable reduction, is easy to perform and has been found to give consistently good results. Posterior open reduction of childhood supracondylar fractures is not associated with an important loss of elbows movement and need not be avoided on this account. No longer has the adage, 'not bad for a supracondylar fracture' held good. We strongly advocate open reduction and internal fixation with K wires fixation of displaced supracondylar fractures in children for the various reasons discussed above in the study.

*Funding: No funding sources*

*Conflict of interest: None declared*

*Ethical approval: The study was approved by the institutional ethics committee*

## REFERENCES

1. Boyd HB, Attenberg AR. Fractures about the elbow in children. Arch Surg. 1944;49:213.
2. Hanlon CR, Ester WL. Fractures in children: a statistical analysis. Am J Surg. 1954;87:312.
3. Mitchell WJ, Adam JP. Supracondylar fractures in children. JAMA. 1961;175:573-7.
4. Weiland AJ, Baltimore SM, Vernon LTT. Surgical treatment of displaced supracondylar fractures of humerus in children. J Bone Joint Surg. 1978;60:657.
5. Ambrosia D. Supracondylar fractures of the humerus-prevention of varus deformity. J Bone Joint Surg. 1972;54:60.
6. Fowles JV, Kassab MT. Displaced fractures of the elbow in children. J Bone Joint Surg. 1974;56:490-500
7. Krurer MH, Regan MW. Completely displaced supracondylar fractures of the humerus in children. Clin Orthop. 1990;256:205-14.
8. Flynn JC, Mathews JG, Benot RL. Blind Pinning of displaced supracondylar fractures of humerus in children. J Bone Joint Surg. 1974;56A:163.
9. Smith L. Deformity following supracondylar fractures of humerus in children. J Bone Joint Surg. 1960;42:245.
10. Gruber, Hudson OC. Supracondylar fractures of humerus in children: end result study of open reduction. J Bone Joint Surg. 1964;46:1245.
11. Sandegard E. Fractures of lower and end of humerus in children treatment and end results. Acta Chir Scand. 1944;89-116.
12. Ramsey RH, Griz. J. Immediate open reduction and internal fixation of severely displaced supracondylar fractures of the humerus in children. Clin Orthop. 1973;90:130.
13. Holmberg L. Fractures in children. Acta Chir Scand. 1945;103.

**Cite this article as:** Kumar A, Padmanabhan K. A clinical study of surgical management of paediatric humeral supracondylar fracture. Int J Res Orthop 2019;5:1088-93.