

Original Research Article

Anterior femoral cut in total knee arthroplasty: a classification proposal

Filipe Medeiros*, António Duarte, Bruno Correia, Maria Carvalho,
João Vide, Ana Paula Fontes, João Paulo Sousa

Department of Orthopaedics, Hospital Particular do Algarve, Portugal

Received: 09 August 2019

Revised: 17 October 2019

Accepted: 25 October 2019

***Correspondence:**

Dr. Filipe Medeiros,

E-mail: filipejmedeiros@gmail.com

Copyright: © the author(s), publisher and licensee Medip Academy. This is an open-access article distributed under the terms of the Creative Commons Attribution Non-Commercial License, which permits unrestricted non-commercial use, distribution, and reproduction in any medium, provided the original work is properly cited.

ABSTRACT

Background: The cut of the anterior femur (CAF) sets the rotation of the femoral component, which could affect patellar tracking, and influence the clinical results on total knee arthroplasty (TKA). The aim of this study was to suggest a classification for anterior femoral cut in TKA.

Methods: Images of anterior femoral cuts were aggregated in different shapes and defined a classification. One-hundred femoral image's cuts were analysed by 5 orthopaedic surgeons, which classified them twice. To analyse inter and intra-observer agreement, the Fleiss Kappa test was used.

Results: The study proposes the following CAF classification, type 1 (one peak) and type 2 (two peaks); subtypes 1 (a) a central base peak, 1 (b) a lateral base peak, 2 (a) two peaks where the smallest is in the lower half, and 2 (b) two peaks where the smallest is in the upper half. In our study, type 2 (a) was the most common type (54.5%), followed by type 1 (b). The analysis showed good intra- and inter-observer agreements (mean K of 0.774 and 0.627, respectively). The intra and inter-observer concordance was statistically significant in all the analyses.

Conclusions: The CAF classification system for TKA is considered a reproducible classification. To our knowledge, there is no study describing a shape's classification of this cut. A slight rotation of the femoral cutting guide could change the axial rotation and positioning of the femoral component. An undesirable cut could lead to different patellofemoral offset and could consequently cause anterior pain and instability.

Keywords: Total knee arthroplasty, Total knee replacement, Cut of anterior femur

INTRODUCTION

Total knee arthroplasty (TKA) is surgical procedure for the treatment of end-stage knee arthritis, with an overall high clinical success. However, approximately 20% of the patients are not satisfied and patellofemoral pain and instability have been found to be one of the most common reasons for revision.¹ The causes of patellofemoral complications are multifactorial, including improper surgical technique and limitations in implant design.² Numerous biomechanical studies suggest difficulty to restore the physiological patellofemoral tracking due to the difference between trochlear implant

and the native trochlea.³ Concerning the surgery, implant positioning and sizing, soft-tissue balancing and the cut of anterior femur (CAF) are critical. The anterior femoral cut sets the rotation of the femoral component, which affects patellar tracking, it is an extremely important step on total knee arthroplasty.⁴ If the anterior cut is too shallow, it will cause overstuffing of the patellofemoral joint. If it is too deep, it will cause notching, and may increase risk for periprosthetic fracture. Tayside classification studies the relationship between anterior femoral notching and a risk of fracture, but the analysis is in lateral view and it is not the most suitable to determine the shape of anterior part of femur. Concerning the

morphology of the distal femur, ratio is important, which represents the width of the femur, but new studies showed that rectangular/trapezoidal variability of the distal femur cannot be ignored. The distal femur is considerably more trapezoidal than most femoral components, and therefore, care must be taken to avoid anterior prosthetic overhang in TKA.⁵ Moreover, external rotation may amplify the asymmetry between the medial and lateral condyles, and exacerbate also prosthetic overhang.⁶ There is a high anatomy variation on distal femur condyles that, resulting in different shapes of trochlear groove and respective cut. Dejour classification is useful to determine the trochlear shape, but insufficient to predict the frontal cut in arthroplasties.⁷ To determine the proper femoral component rotation, several surgical methods have been utilised, like the transepicondylar line, the Whiteside line or the posterior condylar line. These methods have low interindividual reproducibility, and there is no consensus about the best method for frontal femoral sectioning.⁸ Only a few previous studies exist on the accuracy of femoral component rotation using Patient Specific Instrumentation in Total Knee Arthroplasty (PSI-TKA). To our knowledge, there is no study describing a shape's classification of this important cut. The aim of this study was to suggest a classification for anterior femoral cut in TKA.

METHODS

This is a descriptive and comparative study realised in Hospital Privado do Algarve. After ethical approval, pre-operative planning magnetic resonance image (MRI) of 230 patients who underwent TKA (right and left) during 2018, in our institution, were retrospectively randomized and analysed. We aggregate the different anterior femoral cuts and define a classification, according its shape. The classification system proposed by the authors was presented in detail to 5 observers prior to evaluation. One medical student, one orthopaedic resident and three orthopaedic surgeons voluntarily participated in the study. To attest the classification's agreement, 100 femoral MRI image cuts of our initial sample were randomly selected and analysed by them, twice with a week of interval. To analyse inter and intra-observer agreement, the Fleiss Kappa test was used.⁹ This test is the most appropriate when multiple observers and/or

multiple assessments are analysed, and when the evaluation scale presents several nominal or categorical options. The test was interpreted according to with Altman as proportional agreement with correction of chance.¹⁰ Kappa is the coefficient of agreement whose value varies from +1 (perfect agreement), passes through 0 (concordance equal to chance) and -1 (complete disagreement). For the interpretation we used the values described by Landis and Koch and the level of significance considered was 0.05.

RESULTS

Our proposal classification for CAF is type 1 - one peak, (there is no valley) and type 2 - two peaks, there is one valley (at least). The subtypes of type 1 are: 1(a) a central base peak and 1(b) a lateral base peak. The subtypes of type 2 are: 2(a) two peaks where the smallest is in the lower half and 2(b) two peaks where the smallest is in the middle or upper half (Figure 1). Our sampling has an average age of 68.7±7.9 years old. It is composed by 65% of females and 44% of left knees. The type 2(a) was the most common type found in our study (54.5%, 47-67). It was followed by type 1b (26.5%, 15-34) and 1(a) (13%, 5-20). The less common type was 2(b) (6%, 3-9). Table 1 presents the absolute frequencies for each of the observers and for each of their evaluations. The results for intra-observer agreement are presented in Table 2. The K mean value was 0.774, with a variation from 0.652 (FM) to 0.886 (MM), whose interpretation is "Good Concordance"; two observers (RD and MM) were found to have reached an "excellent concordance" value (respectively 0.831 and 0.886). The results for the inter-observer agreement for the first and second moment are presented in Table 3. The inter-observer agreement was performed comparing the first reading of each observer, paired two by two, to make all possible combinations and repeating the analysis after the second reading of each observer. The mean kappa coefficient at first reading was 0.563 with a range of 0.431 (FM-JPS) to 0.677 (JV-MM), which analysis reveals a "Moderate Concordance". The second reading was a mean kappa of 0.627, with a variation of 0.487 (FM-MM) and 0.771 (FM-RD), whose interpretation corresponds to a "Good Concordance". The intra and inter-observer concordance was statistically significant in all the analyses.

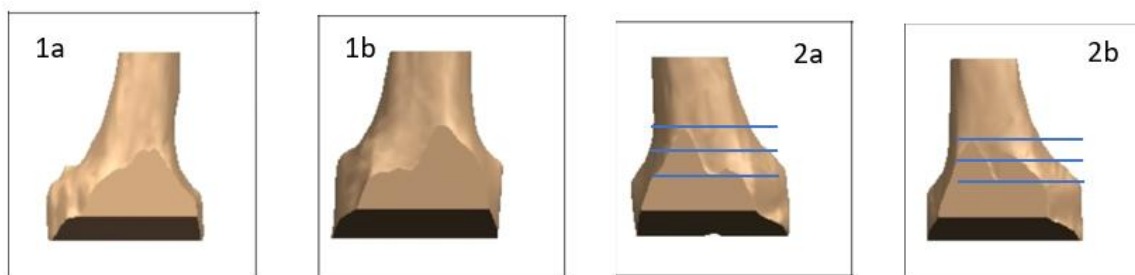


Figure 1: CAF classification: 1 (a) a central base peak, 1 (b) a lateral base peak, 2 (a) two peaks where the smallest is in the lower half, 2 (b) two peaks where the smallest is in the middle or upper half.

Table 1: Absolute frequencies for each of the observers and for each of their evaluations (n=1000).

Classification	Observers										Total, N (%)
	FM		JPS		RD		JV		MM		
	1 st Evn	2 nd Evn	1 st Evn	2 nd Evn	1 st Evn	2 nd Evn	1 st Evn	2 nd Evn	1 st Evn	2 nd Evn	
1a	17	19	11	10	20	21	12	9	5	5	129 (12.9)
1b	25	28	15	24	24	23	34	31	31	29	264 (26.4)
2a	49	47	67	60	48	50	48	53	61	62	545 (54.5)
2b	9	6	7	6	8	6	6	7	3	4	62 (6.2)

Evn: Evaluation.

Table 2: Statistical analyses of intra-observer agreement.

Observers	Fleiss' Kappa index (p value)	CI (95%)	
		Inferior	Superior
FM	0.652 (<0.001)	0.526	0.779
JPS	0.724 (<0.001)	0.591	0.857
RD	0.831 (<0.001)	0.704	0.958
JV	0.776 (<0.001)	0.639	0.912
MM	0.886 (<0.001)	0.731	1.042
Mean value of K	0.774	-	-

Table 3: Statistical analyses of inter-observer agreement between first and second evaluation.

Observers	1 st Evaluation (CI 95%)	2 nd Evaluation (CI 95%)
FM-JPS	0.431 (0.303-0.559)	0.646 (0.515-0.777)
FM-RD	0.619 (0.494-0.745)	0.771 (0.643-0.900)
FM-JV	0.647 (0.518-0.776)	0.531 (0.399-0.662)
FM-MM	0.569 (0.434-0.705)	0.487 (0.351-0.624)
JPS-RD	0.546 (0.418-0.675)	0.675 (0.544-0.805)
JPS-JV	0.442 (0.309-0.576)	0.595 (0.458-0.731)
JPS-MM	0.489 (0.349-0.630)	0.691 (0.548-0.834)
RD-JV	0.660 (0.531-0.790)	0.654 (0.523-0.784)
RD-MM	0.551 (0.415-0.687)	0.583 (0.448-0.718)
JV-MM	0.677 (0.533-0.821)	0.633 (0.488-0.777)
Mean value of K	0.563	0.627

DISCUSSION

The design of the femoral component trochlear compartment is one of the critical factors that affects patellofemoral outcome after TKA. Over time, improvements in femoral component design were developed to create “patella-friendly” designs. In general, these designs incorporate features such as more congruent articulation, a deeper trochlear groove with a raised lateral border, and extension of the trochlea proximally and distally.³ However, incorporating these design elements can result in potential problems. The orientation of the trochlear groove in the coronal plane is a factor previously considered. To our knowledge, there is no study describing a shape’s classification of the anterior femoral cut that we think could be an important improvement to understand patellofemoral issues after TKA. Our proposal classification is simple, easy to reproduce and we showed its agreement with our results. However, there is some shape’s that the type is not clean.

For example, sometimes there is a little variation between 1 (b) and 2 (a). The existence of a peak in the medial condyle is not always well defined. It should be noted that we are evaluating standards of both condyles, therefore, it is considered the 2 major peaks if there are more than 2 peaks, and the millimetric variations should not be considered. In case of doubt, the second peak should not be considered if there isn’t an ascending line after the valley, for example when there is a plateau level and it should be considered 1 (b). (Figure 2)

The axial rotation of the anterior resection plane changes the resection footprint dimension, which leads to coronal rotation of the femoral component. External rotation of the resection plane results in valgus rotation of the trochlear groove and decreased lateral trochlear inclination. The opposite was observed for internal rotation. Cho et al, showed that changing the axial rotation of the anterior cut, the coronal groove of the prosthesis can be altered to lie more closely with the

native groove line (Figure 3).¹¹ As showed in the image, 6° of external rotation corresponds to type 1b, 6° of internal rotation corresponds to type 2b, and original cut corresponds to type 2(a).



Figure 2 (a-c): Image cuts with higher disagreement on classification that must be classified like 1 (b).

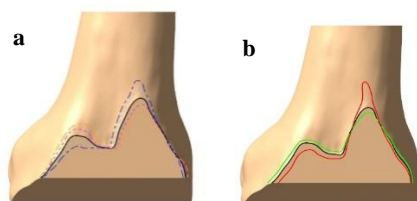


Figure 3: Changes on classification's type with axial (a) and sagittal (b) rotation cut. 6° of external rotation (dark blue line) corresponds to type 1(b), 6° of internal rotation (orange line) corresponds to type 2(b), and original cut (black line) corresponds to type 2(a). Lines: black—original; cyan-3° external rotation; dark blue-6° external rotation; pink-3° internal rotation; orange-6° internal rotation; red-3° of extension; green-3° of flexion.

An internal rotation between 3°-6° tends to be tolerable and an external rotation up to 8° may not cause clinical problems, it is unknown why some patients are more symptomatic than others.¹² Before applying femoral implants, we should be aware if a type 1(a) or 2(b) exists, because it could not simulate the native trochlea. It could be an anatomic variation, but it also could be a slight rotation of the femoral cutting guide, resulting in different type on our classification. Only a few previous studies exist on the accuracy of femoral component rotation using patient specific instrumentation-TKA (PSI-TKA). This method was recently found to be effective in significantly reducing outliers of optimal rotational femoral component alignment.^{13,14} PSI-TKA have the advantage on these cuts when comparing with conventional cuts, whereas the guide rotation is more frequent and can lead easily to an undesirable cut and consequently to different patellofemoral offset. Further investigations comparing the image of anterior cut planned for PSI-TKA and the real shape of the cut intraoperatively are critical for understanding the influence of this cut on decreasing patellofemoral pain and maltracking after TKA. The current authors are presently conducting a study that addresses this point.

Our study has some limitations, namely the classification does not cover all the shapes cut. It could be a type 3 unclassifiable, but this will be very rare, and it is more beneficial that in doubt, one of the existing types should be chosen rather than losing the classification. This is an imageology-based study, without clinical testing. Therefore, the authors are developing a clinical study based on this classification. The final limitation is about the influence on instability patellofemoral issues, because other cuts could also influence them.

CONCLUSION

This new classification system for anterior femoral cut in TKA showed adequate inter-observer and intra-observer agreement. Therefore, we recommend applying the proposed classification system in clinical practice when TKA is being done. This classification system could help to understand part of these problems, but more research is needed.

Funding: No funding sources

Conflict of interest: None declared

Ethical approval: The study was approved by the institutional ethics committee

REFERENCES

1. Baker PN, van der Meulen JH, Lewsey J. The role of pain and function in determining patient satisfaction after total knee replacement: data from the National Joint Registry for England and Wales. *J Bone Joint Surg.* 2007;89-B:893-900.
2. Varadarajan K, Rubash HE, Li G. Are current total knee arthroplasty implants designed to restore normal trochlear groove anatomy? *J Arthroplasty.* 2011;26:274-81.
3. Kulkarni SK, Freeman MA, Poal-Manresa JC. The patellofemoral joint in total knee arthroplasty: is the design of the trochlea the critical factor? *J Arthroplasty.* 2000;15:424-9.
4. Gujarathi N, Putti AB, Abboud RJ. Risk of periprosthetic fracture after anterior femoral notching. *Acta Orthopaedica.* 2009;80(5):553-6.
5. Bonnin M, Saffarini M, Bossard N. Morphometric analysis of the distal femur in total knee arthroplasty and native knees. *Bone Joint J.* 2016;98-B(1):49-57.
6. Bonnin M, Saffarini M, Nover L. External rotation of the femoral component increases asymmetry of the posterior condyles. *Bone Joint J.* 2017; 99-B(7):894-903.
7. Dejour D, Reynaud P, Lecoulte B. Douleurs et instabilité rotulienne: Essai de classification. *Med Hyg.* 1998;56:1466-71.
8. Cho Y, Lee MC. Rotational alignment in total knee arthroplasty. *AP-SMART: Asia-Pacific Journal of Sports Medicine, Arthroscopy, Rehabilitation and Technology.* 2014;9(4):113-8.

9. Landis KG, Koch GG. The measurement of observer agreement for categorical data. *Biometrics.*1977;33(1):159-74.
10. Altman DG. *Practical statistic for medical research.* 3rd edition. 1995: 403-409.
11. Cho KJ, Erasmus PJ, Muller JH. The effect of axial rotation of the anterior resection plane in patellofemoral arthroplasty. *Knee.* 2016;23(5):895–9.
12. Ghosh KM, Merican AM, Iranpour F. The effect of femoral component rotation on the extensor retinaculum of the knee. *J Orthop Res.* 2010;28(9):1136-41.
13. Heyse T, Tibesku CO. Improved femoral component rotation in TKA using patient-specific instrumentation. *Knee.* 2014;21(1):268-71.
14. Schotanus MGM, Thijs E, Heijmans M. Favourable alignment outcomes with MRI-based patient-specific instruments in total knee arthroplasty. *Knee Surg Sports Traumatol Arthrosc.* 2018;26(9):2659-68.

Cite this article as: Medeiros F, Duarte A, Correia B, Carvalho M, Vide J, Fontes AP, et al. Anterior femoral cut in TKA: classification proposal. *Int J Res Orthop* 2020;6:7-11.