

## Original Research Article

# Functional outcome of modified technique of intramedullary fixation of diaphyseal humeral fractures

Mohit Sharma<sup>1\*</sup>, Anil Golhar<sup>2</sup>, Sushil Mankar<sup>2</sup>, Rishav Krishna<sup>1</sup>

<sup>1</sup>Department of Orthopaedics, Dr. Baba Saheb Ambedkar Hospital and Medical College, Rohini, New Delhi, India

<sup>2</sup>Department of Orthopaedics, N.K.P.S.I.M.S., Lata Mangeshkar Hospital, Nagpur, Maharashtra, India

**Received:** 02 July 2019

**Revised:** 14 December 2019

**Accepted:** 16 December 2019

### \*Correspondence:

Dr. Mohit Sharma,

E-mail: [drmohitsharma1989@gmail.com](mailto:drmohitsharma1989@gmail.com)

**Copyright:** © the author(s), publisher and licensee Medip Academy. This is an open-access article distributed under the terms of the Creative Commons Attribution Non-Commercial License, which permits unrestricted non-commercial use, distribution, and reproduction in any medium, provided the original work is properly cited.

## ABSTRACT

**Background:** The aim of this study was to evaluate the functional outcomes with intramedullary fixation using flexible nails and to follow up for any other complications.

**Methods:** Study was a prospective study in Lata Mangeshkar Hospital, Nagpur during 2014 to 2016. All the patients enrolled in the study were briefed about the nature of the study. All cases in this series were operated by combined antegrade and retrograde approach.

**Results:** Total of 30 patients of closed diaphyseal humeral fractures was studied. Maximum i.e., 16 (53.33%) were in the age range of 21-40 years, followed by 10 (33.33%) patients in the range of 41-60 years. 21 (70%) cases had fracture union between 10-16 weeks with a score of 8 points, followed by 8 (26.67%) patients with fracture union duration of less than 10 weeks with a score of 10 points. Only one of the patients landed up with non-union. The mean functional score of patients at 3rd month was  $64.03 \pm 4.99$ , 9th month was  $73.46 \pm 2.56$ . 86.66% patients had good to fair outcome, 3.33% patient each had excellent and poor outcome.

**Conclusions:** Comparing results of our study with other studies, we found that our results are almost comparable but not better than open reduction and plating. Complications encountered in our series are comparatively less compared to those encountered during interlock nailing. The trauma to rotator cuff is minimum and this method is good alternative method. Thus, multiple nailing gives better functional outcomes as compared to locked nail.

**Keywords:** Dynamic compression plating, intramedullary nailing, Diaphyseal humeral fractures

## INTRODUCTION

Trauma has been the leading cause of mortality and morbidity since the beginning of mankind and is on the rise at present. The victim of bony injury, often the sole earning member of the family, faces prolonged immobilization, loss of wages and tough time for the entire family. Besides, the patient often has to live with the sequelae of stiff joints and functional disability. Early restoration of joint mobility, return to normal physiologic function and minimal morbidity is now regarded as the ideal treatment for fractures. A study by World Health Organization in 2002 showed that fracture humerus

accounted for 4.8% of non-fatal road traffic injuries. Diaphyseal fractures of humerus account for 3% of all fractures.<sup>1</sup>With increasing road traffic accidents, this percentage is likely to increase in the future. Fracture of humerus is regarded as the most challenging fracture of the upper limb to be treated. Irreparable damages can occur if humerus fractures are not understood and treated properly.

Diaphyseal fractures of humerus have been treated conservatively since ages with good results. Sir John Charnley in his thesis, "The closed treatment of common fractures" stated, it is perhaps one of the easiest major

long bone fractures, to be treated by conservative methods.<sup>2</sup> However, conservative treatment has its demerits such as prolonged limb immobilization, the need for constant co-operation of patient and repeated hospital visits. Loss of reduction in the plaster cast invariably leads to malunion. Moreover, it cannot be recommended in every case like unstable fractures (spiral/ long oblique), comminuted fractures, segmental fractures, pathological fractures, open fractures, fractures with delayed union or nonunion, fractures with radial nerve injuries or vascular injury and such fractures require operative line of treatment.

Operative management causes early mobilization and improves patient comfort, but it carries the risk of technical errors and post-operative complications, infections, nerve injuries etc. The operative line of management of diaphyseal fractures of humerus involves open reduction and internal fixation with plate osteosynthesis or intramedullary implant or external fixation.

With the advent of rigid intramedullary nailing with transverse locking screws, surgeons are now trying to couple the advantages of conservative management with the advantages of operative treatment.

Closed interlock nailing involves minimal surgical intervention, biological fixation, no periosteal stripping with rotational and torsional stability, anatomical reduction, early mobilization and preservation of hematoma. With the advent of image intensifier control, this method has become extremely easy. However, it has disadvantages like rotator cuff impingement and restricted elbow movements. Plate osteosynthesis has given high rates of fracture union with anatomical reduction and good compression across fracture site, with no damage to the rotator cuff and the elbow joint, but has the disadvantage of excessive periosteal stripping, extensive incision, increased chances of infection, nerve damage and less secured fracture of osteopenic bone.<sup>3</sup> Further there is a stress shielding of bone by the plate and reduced strength of union due to primary bone healing compared to the callus healing seen in biological fixation with intramedullary nailing.

## **METHODS**

This was a prospective study carried out in a tertiary health care centre in Maharashtra in Lata Mangeshkar Hospital, Nagpur between July 2014 to July 2016 over a period of 2 years with total sample size being 30 patients.

### ***Inclusion criteria***

Patients with age >18 years, both genders, patients with closed humeral diaphyseal fractures and those who were willing for the study.

### ***Exclusion criteria***

Patients with age <18 years, who failed closed treatment, patients with all other complex humeral fractures, those associated with intra-articular fractures and injuries to the brachial plexus, delayed union, nonunion/malunion, patients with infection, those who are having compound fractures with neurovascular deficit and vascular injury and those not willing for the study.

This surgery was performed under regional or general anaesthesia.

### ***Approach***

All cases in this series were operated by combined antegrade and retrograde approach using an extra rotator cuff entry point or through greater tuberosity.

### ***Positioning of the patient***

The patient was placed in supine position on a radiolucent table. The head was turned to the opposite side to increase exposure to the shoulder. A cloth or bolster or sand bag was placed between the scapular regions, so as to achieve 30 degree of extension of the shoulder, which made the entry point more accessible.

### ***Patient preparation***

Preoperative scrubbing was done using povidone iodine and Cutasept for atleast 10 minutes and mopped off with spirit. Painting was done with povidone iodine, spirit and Cutasept for skin preparation. Draping was done with sterile sheets. The forearm and hand were draped separately.

### ***Incision and entry point***

A minimal incision was taken after palpation of the greater tuberosity (approximately 1.5 cm). A modified insertion point located 1 cm below the crest of the greater tuberosity was identified in a region outside the articular surface and rotator cuff area (Figure 1). The appropriate nail diameter was determined by measuring the diameter of the narrowest part of the medullary canal (medullary isthmus) on a radiograph and the nail diameter chosen was about 40-60% of medullary isthmus inserted from distal humerus entry point (Figure 2 c,e). Flowering up of the nails proximally with antegrade nail inserted from extra rotator cuff entry point and fracture site reduction can be seen in (Figure 2d).

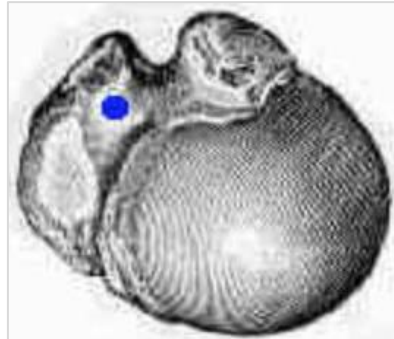
### ***Post-operative management***

Check radiograph was taken after surgery (Figure 3a). The operated extremity was given a posterior slab. The antegrade nail was removed at 4 weeks to avoid any shoulder impingement as a minor OPD procedure under local anaesthesia. Rehabilitation was begun immediately,

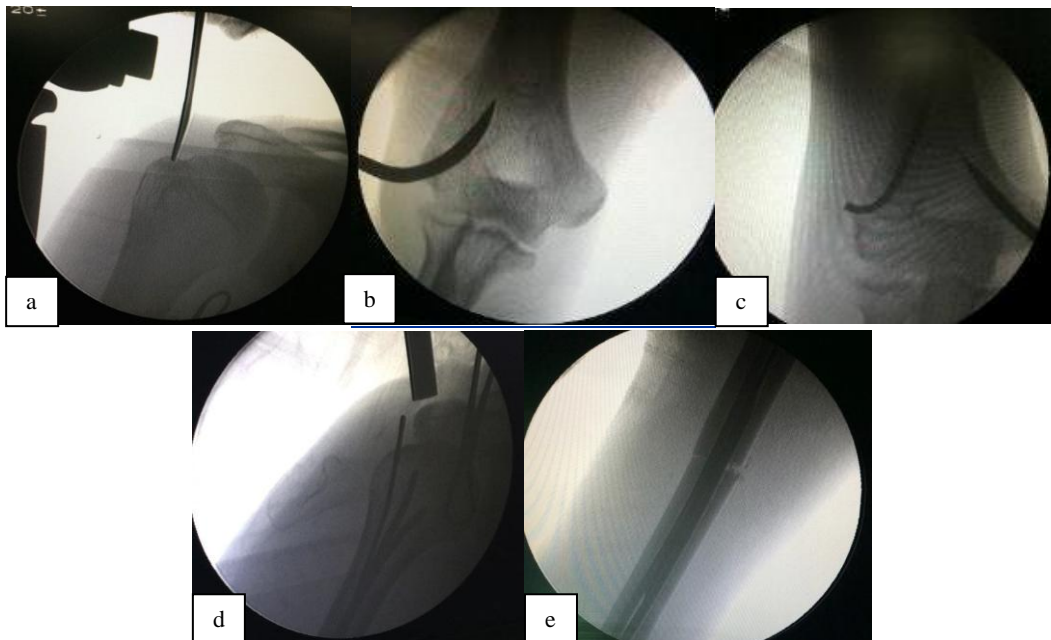
allowing flexion and extension at elbow till 6 weeks following which abduction was started after the fracture was stable. 1<sup>st</sup> dressing was done on the 3<sup>rd</sup> post-operative day. 2<sup>nd</sup> dressing was done on the 7<sup>th</sup> post-operative day. Discharge was done after 11<sup>th</sup> post-operative day, after removal of sutures.

**Post-operative medication**

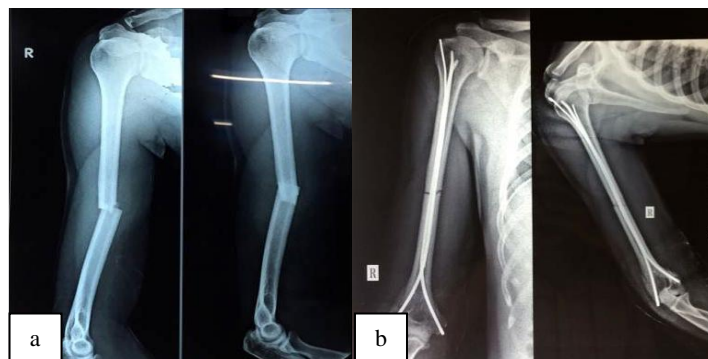Intravenous antibiotic combination of cephalosporins and aminoglycosides was given for 72 hours with adequate analgesia been maintained.



**Figure 1: Extra rotator cuff entry point.**



**Figure 2: (a) C arm image of extra rotator cuff entry point, (b) insertion point lateral condyle, (c) insertion point for medial condyle, (d) flowering up of nails proximally and (e) fracture site reduction.**



**Figure 3: (a) Preoperative radiographs and (b) postoperative radiograph.**

## RESULTS

A total of 30 patients of closed diaphyseal humeral fractures were studied and various observations were analyzed. The findings of the present study are summarized as follows: maximum i.e., 16 (53.33%) were in the age range of 21-40 years, followed by 10 (33.33%) patients in the range of 41-60 years. 73.33% of patients were males, while 26.67% patients were females. 76.67% patients met with road traffic accidents, while 13.33% fell from height. 6.67% patients were hit by blunt objects while 3.33% patient met with an assault.

Maximum i.e., 43.33% were in the A3 group, followed by 33.33% patients in the B2 group. 63.33% patients had fracture in the middle third, 26.67% patients in the lower third while 10% in the upper third. 20% patients had associated injuries.

The mean diameter of 1<sup>st</sup> retrograde nail diameter was 2.82±0.45 mm, of 2<sup>nd</sup> retrograde nail was 2.73±0.31 mm and that of antegrade rush nail was 2.33±0.36 mm. The median blood loss was 1 mop, while the mean number of mops used was 1.03±0.18. The median post-operative hospital stay was 10 days, while the mean was 10.033±2.008 days. The median pain score of patients was 3.00, while mean was 3.03±1.25. The median duration of healing was 11 weeks, while the mean was 10.8±2.07 weeks (Table 1).

**Table 1: Duration of healing.**

Statistical parameters	Duration in weeks
Mean	11
Median	10.8
SD	2.07

**Table 2: Time of fracture union.**

Time of fracture union (weeks)	Point	N (%)
<10	10	8 (26.67)
10-16	8	21 (70)
17-20	6	0
20-30	4	0
>30	2	0
Non union	0	1 (3.33)

21 (70%) cases had fracture union between 10-16 weeks with a score of 8 points, followed by 8 (26.67%) patients with fracture union duration of less than 10 weeks with a score of 10 points. Only one of the patients landed up with non-union (Table 2). The mean functional score of patients at 3<sup>rd</sup> month was 64.03±4.99, at 6<sup>th</sup> month was 70.63±3.27 and at 9<sup>th</sup> month was 73.46±2.56 (Table 3). 86.66% patients had good to fair outcome, while 3.33% patient each had excellent and poor outcome (Table 4). 26.7% patients had complications out of which shoulder stiffness about 10% and superficial infection about 10%

which recovered with antibiotic treatment (Table 2). Only 2 patients had to undergo re-surgery, 1 had non-union and 1 had a re-fracture and implant failure for which plating was done (Table 5).

**Table 3: Functional score.**

Time point	Mean	SD	Median
3 <sup>rd</sup> month	64.03	4.99989	65
6 <sup>th</sup> month	70.63	3.27165	70
9 <sup>th</sup> month	73.46	2.56485	75

**Table 4: Functional outcome.**

Functional outcome	N (%)
Excellent	1 (3.33)
Good	13 (43.33)
Fair	13 (43.33)
Poor	1 (3.33)
Lost to follow up	2 (6.67)
Total	30

**Table 5: Complications.**

Complications	N (%)
Non union	1 (3.33)
Shoulder stiffness	3 (10)
Superficial infection	3 (10)
Implant failure	1 (3.33)
Radial nerve injury	0

## DISCUSSION

Treatment of humeral shaft fractures has been mainly conservative with very good results. There is enough literature available to suggest that even today conservative line of treatment gives excellent results as shown by Sarmiento et al.<sup>4,5</sup> However, the cumbersome casting and extensive rehabilitation period has led to go for alternative methods of treatment in humeral shaft fractures. As seen from the literature, open reduction and plating is still considered to be gold standard and complications like radial nerve palsy, infection and operating time has probably led surgeons to go for intramedullary nailing.

To begin with, locked intramedullary nails were used for femoral and tibial fractures and the success of this treatment in femoral and tibial fractures has been the important driving point for surgeons to go for locked nailing in fractures of the shaft of the humerus.

The antegrade interlock nail passed through the greater tuberosity has many problems like stiffness of shoulder, impingement and most importantly the chronic injury to rotator cuff. At the time of insertion, there is no way to prevent injury to rotator cuff. This ultimately leads to functional problems of shoulder movement. Therefore, there are a group of surgeons who suggest that one should

open the rotator cuff while entering the tuberosity and repair it properly after the procedure is over.

This means that when the nail is removed, the same procedure should be repeated. Tampering of the rotator cuff twice will lead to damage to the rotator cuff structure and ultimately poor functional recovery of shoulder. Closed nailing has some advantages like retaining the fracture hematoma, less infection, less chances of radial nerve injury; but the injury to rotator cuff and its consequences probably overshadows the advantages of antegrade locked nailing.

As a result of the problems faced by antegrade locked nail in diaphyseal humerus fractures, we decided to undertake this study with the aim to minimize trauma to the rotator cuff and achieve reasonably rigid fixation so that mobilization of shoulder and elbow could be started early.

In our series, the antegrade entry point of flexible nail of diameter 2.5 mm from the tuberosity hardly caused any damage to the rotator cuff compared to antegrade nail of 8 mm and more. The entry point of retrograde flexible nail was passed upward from lateral condyle, fanned out in the proximal part of humeral head. This gave good fixation. 2-3 nails could be passed from lateral and medial condyles of humerus. Plaster/ brace were used post-operatively for 6 weeks to provide additional stability.

In majority of cases in our study, fractures were fixed within 10 days of hospital admission.

#### **Age distribution**

In our study, maximum i.e., 16 (53.33%) patients were in the age range of 21-40 years, followed by 10 (33.33%) patients in the range of 41-60 years. This correlates with other studies- 39.6 years in a study by Lal et al, 43.5 years in a study by Rommens et al, 39.5 years in a study by Foster et al, 69% in age group 15-44 years in a study by Gichuhi et al and 40.3 years in a study by Tytherleigh-Strong et al.<sup>6-9</sup>

#### **Gender distribution**

In our study, 73.33% of patients were males, while 26.67% patients were females which are consistent with McCormack et al, who had 68% male predominance, Lin et al with 65% male predominance and Tytherleigh-Strong et al with 68% male predominance.<sup>9-11</sup>

#### **Duration of healing**

In our study, the median duration of healing was 11 weeks, while the mean was  $10.8 \pm 2.07$  weeks as compared to studies by Lin et al and Lal et al whose mean duration of healing was 8.6 and 8.38 weeks respectively.<sup>6,11</sup> Slightly higher mean time of union (12.6 weeks) was reported by Rommens et al, 6.3 to 9.8 weeks by

Changulani et al, Chapman et al and being higher by Putti et al who reported 18 weeks in Intramedullary nail group.<sup>7,12,13</sup>

#### **Mode of fracture**

In our study, the most common mode of fracture was road traffic accidents 76.67% which is congruous to a study of 78 patients done by al who reported 61% fractures caused by road traffic accidents. Similarly, 66.6% fractures were caused by road traffic accidents in a study by Vishnu et al.<sup>3,14</sup>

#### **Type of fracture based on AO classification**

In our study, 60% fractures were A type of which 43.33% fractures were A3 type. This correlates with 35.29% Type A3 fractures by Putti et al, 22% Type A3 fractures by Sharma et al, 23.07% Type A3 fractures by Denies et al and 62.5% Type A fractures by Vishnu et al.<sup>3,6,15</sup>

#### **Anatomical location of fracture**

In our study, 63.33% of fractures were seen in the middle third of humerus, 26.67% in the lower third and 10% in the upper third. This is consonant with other studies- 41% in mid shaft by Igbigbi et al, 43.2% in middle third by Ekholmfound et al and 64% in mid shaft by Tytherleigh-Strong et al.<sup>9,16</sup>

#### **Average blood loss**

The average blood loss in our study measured in terms of mops used was 1 mop. This is consistent with less than one mops reported by Vishnu et al.<sup>3</sup>

#### **Post-operative hospital stay**

In our study, post-operative hospital stay was a mean of 10.03 days which correlates with 8.76 days by Wali et al, 6.53 days by Fan et al, 14 days by Kumar et al and 2-8 days by Vishnu et al.<sup>3</sup>

#### **Functional outcome**

In our study, the average functional score achieved at 9<sup>th</sup> month was  $73.46 \pm 2.56$ . 86.66% patients had a good to fair score. In their study, Denies et al, 67.3% patients had excellent functional outcomes while 22.4% patients had good outcomes.<sup>13</sup>

#### **Complications**

The most common complication observed in our study was superficial infection (10%) and shoulder stiffness (10%). In their study, Kasturi et al found shoulder stiffness in 5 patients (20%). Bhandari et al reported that 6 out of 28 patients (21%) had shoulder stiffness, Changulani et al reported 16% shoulder pain and decreased shoulder.<sup>12,17</sup>

Movements for intramedullary nail group. Patients with superficial infection in our study were managed with antibiotics and wound dressing.

Mc Cormack et al quoted that of 44 patients, antegrade nailing was done in 6 patients.<sup>10</sup> Of these 6 patients, shoulder impingement was reported in as high as 5 patients. In our study, the antegrade flexible nail was removed at 4-6 weeks as a minor outpatient procedure under local anaesthesia and hence, the problem of impingement was avoided.

### **Rate of non-union**

The rate of non-union in our study was only 3.33% as compared to 8.2% in a study by Denies et al.<sup>13</sup> Hems et al quoted non-union rate as high as 30% in antegrade nailing resulting in poor function.<sup>18</sup> Thus, compared to above series our non-union rate is very negligible.

Radial nerve injury is a common complication of humeral shaft fractures occurring in upto 18% of closed injuries. Most commonly radial nerve injuries are associated with middle third spiral humeral shaft fractures. We were fortunate enough and did not encounter any associated radial nerve injury in our series.

Flinkkila et al quoted that correctly placed antegrade nail does not pose much problem in shoulder function, however, in a blind procedure like closed nailing, it is not mentioned how you can enter correctly through the rotator cuff.<sup>19</sup>

Rommens et al found better results with retrograde nailing as compared with antegrade nailing and plating.<sup>7</sup> Since we did not compare our results with plating, we cannot comment about the plating part, but retrograde flexible nails has given us better results which is in consonant with findings by Rommens et al.<sup>7</sup>

Thus, retrograde multiple nailing gives better functional outcomes as compared to antegrade locked nail. However, larger series with more follow ups are needed to derive a proper conclusion. With a small sample size of 30 patients and short follow up duration of 2 years, this method can be recommended as an alternative to locked intramedullary nailing for diaphyseal humeral fractures.

### **CONCLUSION**

On comparing results of our study with other studies, we found that our results are almost comparable but not better than open reduction and plating. Complications encountered in our series are comparatively less as compared to those encountered during interlock nailing does resulting in a better functional outcome. The trauma to rotator cuff is minimum and this method is a good alternative method as compared to interlocked nail.

*Funding: No funding sources*

*Conflict of interest: None declared*

*Ethical approval: The study was approved by the institutional ethics committee*

### **REFERENCES**

1. Available at: [http://www.who.int/entity/violence\\_injury\\_prevention/publications/road\\_traffic/world\\_report/chapter2.pdf](http://www.who.int/entity/violence_injury_prevention/publications/road_traffic/world_report/chapter2.pdf). Accessed at: 28 June 2019.
2. Charnley J. The closed treatment of common fractures. 3rd edition. 1996: 99.
3. Vishnu M, Kanthimathi B. Short Term Results of Functional Outcome of Plate Osteosynthesis vs Antegrade Intra Medullary Interlocking Nailing In The Treatment of Fractures of Shaft Humerus. Int J Modern Res Rev. 2015;3(10):955-9.
4. McKee MD, Larsson S. Humeral Shaft Fractures. In: Bucholz RW, Court-Brown CM, Heckman JD, Tornetta P (ed). Rockwood and Green's Fractures in Adults. Philadelphia: Lippincott Williams & Wilkins; 2010.
5. Beaty JH. Humeral shaft fractures: Orthopaedic Knowledge Update. Rosemont, Ill: American Academy of Orthopaedic Surgeons; 1999: 278-86.
6. Lal Y, Sharma S, Krishna LG, Ahmed A: Humeral shaft fractures treated by undreamed interlocking nail. Indian J Ortho. 1993;33(3).
7. Rommens PM, Ver bruggen J, Bross P. Retrograde interlocking nailing of fracture of the humeral shaft – clinical study. Unfallchirurg. 1995;98(3):133-8.
8. Foster RJ, Dixon GL, Bach AW, Appleyard RW, Green TM. Internal fixation of fractures and nonunion of humeral shaft : Indications and Results in a multi-Center study. J Bone Joint Surg Am. 1985;67(6):857-64.
9. Tytherleigh-Strong G, Walls N, McQueen MM. The epidemiology of humeral shaft fractures. J Bone Joint Surg Br. 1998;80:249-53.
10. Mc Cormack RB, Brien D, Buckley RE, McKee MD. Fixation of fractures of the shaft of humerus by dynamic compression plate or intermedullary nail a prospective randomized trial. J Bone Joint Surg Br. 2000;82A:336-9.
11. Lin J. Treatment of humeral shaft fractures with the humeral interlocked nail and comparison with plate fixation. J Bone Joint Surg Br. 1998;44A(5):859-64.
12. Changulani M, Jain UK, Keswani T. Comparison of the use of the humerus intramedullary nail and dynamic compression plate for the management of diaphyseal fractures of the humerus. A randomised controlled study. Int Orthop. Int Orthop. 2007;31(3):391-5.
13. Chapman JR, Henley MB, Agel J, Benca PJ. Randomized prospective study of humeral shaft fracture fixation: intramedullary nailings versus plates. J Orthop Trauma. 2000;14:162-6.
14. Kivi MM, Soleymanha M, Haghparast-Ghadim-Limudahi Z. Treatment Outcome of Intramedullary Fixation with a Locked Rigid Nail in Humeral Shaft Fractures. Arch Bone Joint Surg. 2016;4(1):47-51.

15. Denies E, Nijs S, Sermon A, Broos P. Operative treatment of humeral shaft fractures: comparison of plating and intramedullary nailing. *Acta Orthop Belg.* 2010;76(6):735-42.
16. Igbigbi P S, Manda K. Epidemiology of humeral fractures in Malawi. *International Orthopaedics (SICOT).* 2004;28:338.
17. Kasturi A, Chokkarapu R. Comparison of Outcomes of Dynamic Compression Plate and Interlocking Intramedullary Nail for Fracture Shaft of Humerus: a Prospective Study. *Int J Contemporary Med Res.* 2015;1(1):34-7.
18. Hems TE, Bhullar TP. Interlocking nailing of humeral shaft fractures: Oxford experience 1991 to 1994. *Injury.* 1996;27(7):485-9.
19. Flinkkilä, T., Hyvönen, P., Siira, P. et al. *Arch Orthop Trauma Surg.* 2004;124:537.

**Cite this article as:** Sharma M, Golhar A, Mankar S, Krishna R. Functional outcome of modified technique of intramedullary fixation of diaphyseal humeral fractures. *Int J Res Orthop* 2020;6:78-84.