

## Case Report

# Multiple extradigital glomus tumors of the ankle and foot with limb hypoplasia in a child: a case report

Chiao Yee Lim\*, Sijie Ng, Suryasmi Duski, Ping Ching Chye

Department of Orthopaedic Surgery, Kuala Lumpur Hospital, Jalan Pahang, Kuala Lumpur, Malaysia

**Received:** 18 May 2019

**Accepted:** 04 June 2019

**\*Correspondence:**

Dr. Chiao Yee Lim,

E-mail: [chiaoyee@hotmail.com](mailto:chiaoyee@hotmail.com)

**Copyright:** © the author(s), publisher and licensee Medip Academy. This is an open-access article distributed under the terms of the Creative Commons Attribution Non-Commercial License, which permits unrestricted non-commercial use, distribution, and reproduction in any medium, provided the original work is properly cited.

### ABSTRACT

Glomus tumors are rare tumors, and mostly occur in the fingertips and/ or subungual location. Multiple extradigital glomus tumors are extremely rare. We hereby described a rare case of multiple extradigital glomus tumor of the ankle and foot in a 11 year old girl with hypoplasia of the affected limb. The patient presented with swellings over her right ankle and foot for the past 5 years. The swellings were initially painless but became painful for the past 15 months. On examination, patient's right leg and foot appeared to be smaller when compared to the left side. There were multiple vague swellings over the dorsum of right foot and lateral aspect of right ankle, which were very tender to touch. There was no overlying skin changes observed. Magnetic resonance imaging showed multiple well defined, encapsulated lesions of varying sizes at the level of distal third right fibula and foot. The lesions appeared isointense to muscle in T1-weighted image, hyperintense in T2-weighted image with enhancement post-contrast. Excision biopsy of the right lateral distal leg swelling was performed. Histopathological examination of the excised mass confirmed the diagnosis of glomus tumor. In view of her parents were not keen for any further surgical intervention, the patient will be evaluated regularly, and any enlarging painful lesions will be excised as required. The clinical diagnosis of multiple extradigital glomus tumors is much more problematic due to its rarity. The physicians must be aware of this differential diagnosis so that early diagnosis and treatment could be administered to the patients.

**Keywords:** Glomus tumor, Extradigital glomus tumor, Multiple glomus tumors

### INTRODUCTION

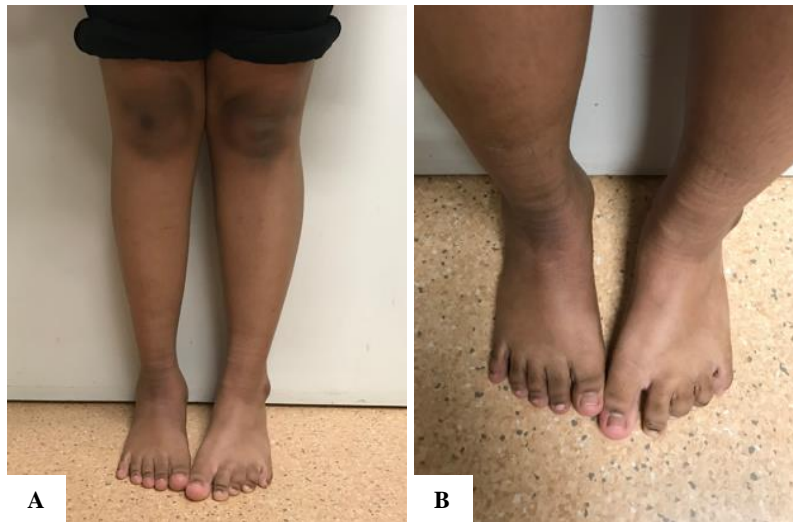
A glomus body is a neuromyoarterial body found within the reticular dermis that function as a specialized form of arteriovenous anastomosis, which regulates blood flow to the skin.<sup>1</sup> Glomus tumors are neoplasms of the normal glomus body. They are rare tumors, although glomus tumors may occur throughout the body, up to 75% occur in the hand with 50–65% of these occurring in the fingertips and/ or subungual location.<sup>2,3</sup> Besides hand, there are rare cases of extradigital glomus tumors reported in the wrist, forearm, elbow, arm, shoulder, buttock, thigh, knee, leg, ankle, foot, back, nose, cheek, ear lobe and trachea by Schiefer et al in their case series

over 20 years duration.<sup>1</sup> They also found out that extradigital glomus tumors were most commonly diagnosed between the fourth and seventh decades of life, slightly later in comparison to previous studies of lesions limited to the hand that showed a peak incidence in the third to fifth decades.<sup>1,4</sup> Literature review on extradigital glomus tumor among pediatric population found only one case report of extradigital glomus tumor of the ankle in a 15 months toddler.<sup>5</sup> Multiple glomus tumors are extremely rare, representing only 10% of all cases of glomus tumors.<sup>6</sup> We hereby described a rare case of multiple extradigital glomus tumors of the ankle and foot in a 11 year old girl with hypoplasia of the affected limb.

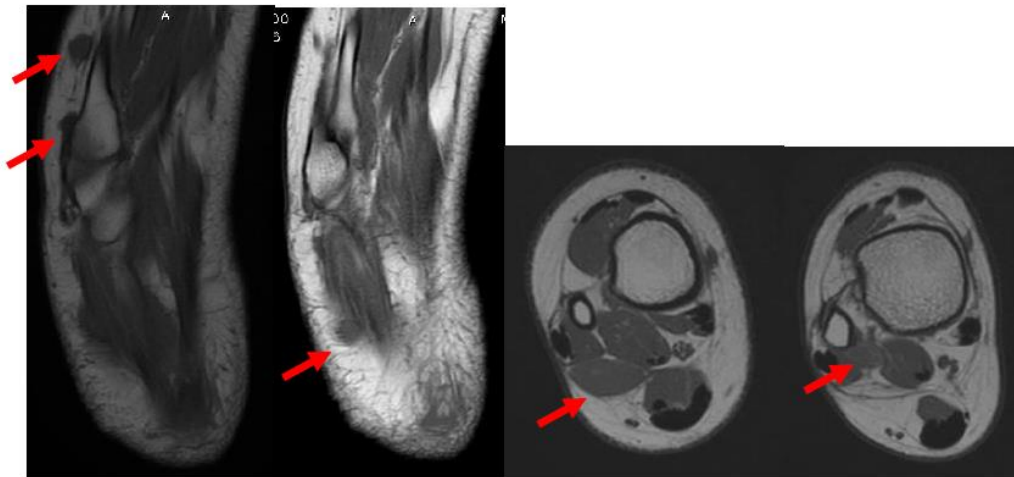
## CASE REPORT

A 11 year old girl presented with swellings over her right ankle and foot for the past 5 years. The parents first noticed the swellings when the patient was 6 years old. The swellings were initially painless but became painful for the past 15 months. The parents brought her for traditional massage prior to seeking medical attention, however her symptoms were not relieved, but the pain was further aggravated following each massage therapy. There was no other significant past medical or surgical

history. No one else in her family had similar problem. On examination, patient was a well build girl, her right leg and foot appeared to be smaller when compared to her contralateral side (Figure 1). There were multiple vague swellings over the dorsum of right foot and lateral aspect of right ankle, which were very tender to touch. There was no overlying skin changes observed. Distal pulses were palpable and comparable on both sides, and there was no neurological deficit of right lower limb on examination.



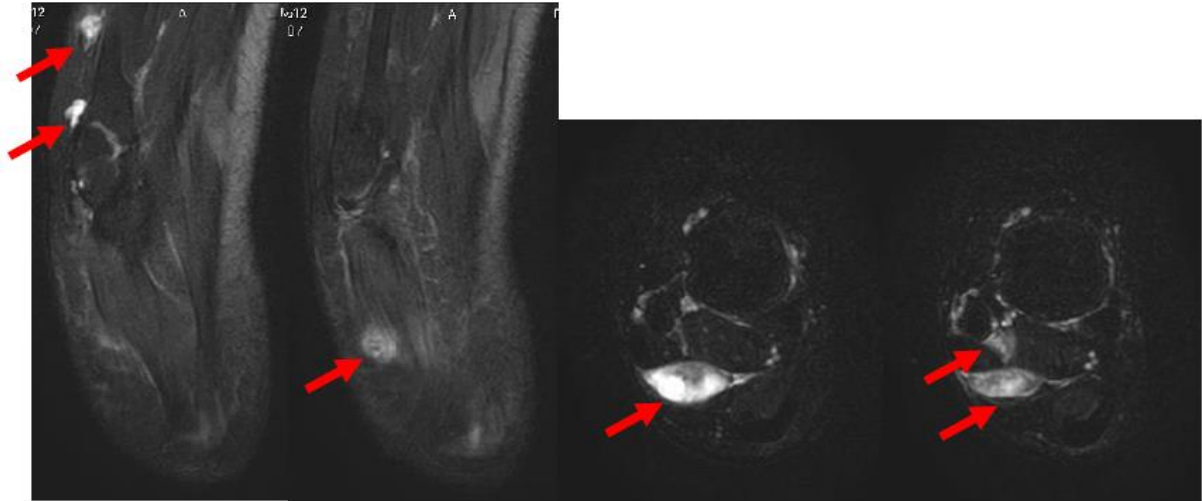
**Figure 1: (A and B) Patient's affected right leg and foot appeared smaller when compared to the contralateral side.**



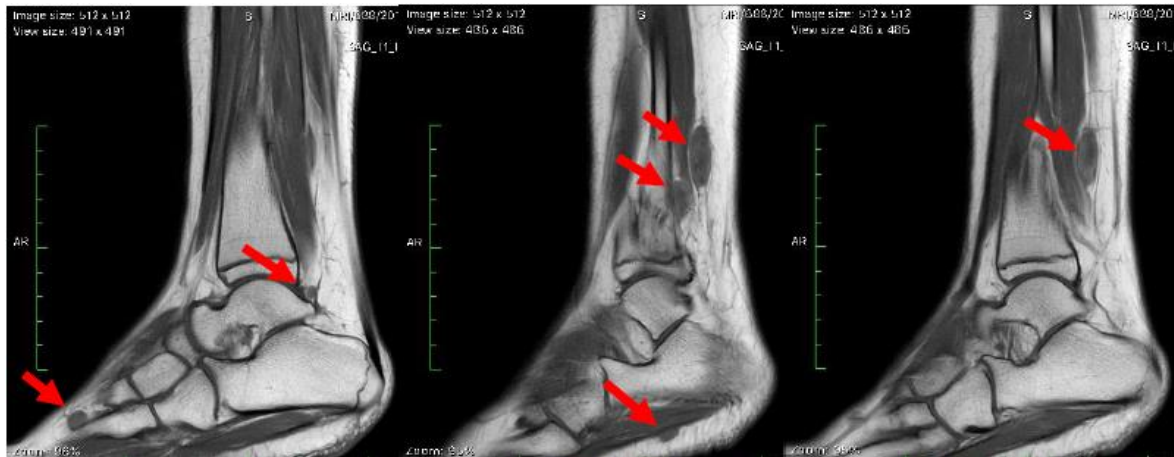**Figure 2: Axial view of T1-weighted image (T1WI) showed multiple lesions of varying sizes (as marked by red arrows) in the right leg and foot which appeared isointense to muscle.**

Magnetic resonance imaging (MRI) examination showed multiple well defined, encapsulated lesions of varying sizes at the level of distal third right fibula and foot. There were approximately 8 lesions found on the MRI scan. The lesions appeared isointense to muscle in T1-weighted image (T1WI), hyperintense in T2-weighted image (T2WI) with enhancement post-contrast (Figure 2-5). Excision biopsy of the right lateral distal leg swelling

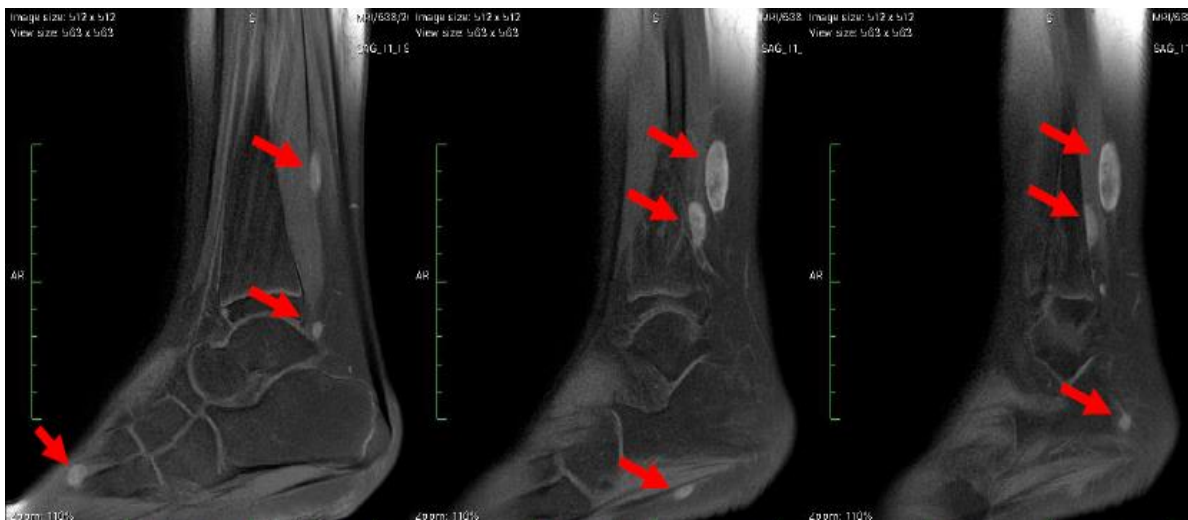was performed, this particular swelling was chosen for excision biopsy as patient informed that this was the most painful swelling. Intra-operatively we noted well encapsulated deep red purplish soft tissue mass bounded by the flexor hallucis longus and peroneus brevis anteriorly and achilles tendon posteriorly (Figure 6). The excised mass measured approximately 2.3×2.0×2.5 cm<sup>3</sup> in size. Histopathological examination (HPE) of the excised mass confirmed the diagnosis of glomus tumor.



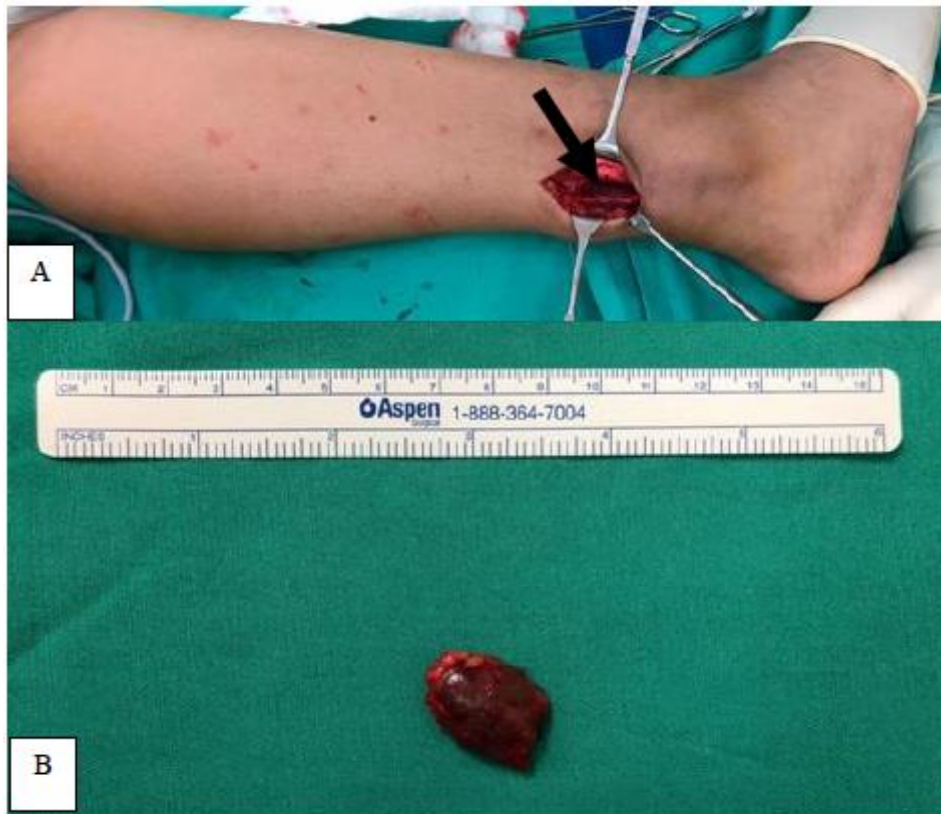**Figure 3: Axial view of fat saturated T2WI showed multiple hyperintense lesions of varying sizes (as marked by red arrows) in the right leg and foot.**



**Figure 4: Sagittal view of T1WI showed multiple lesions of varying sizes (as marked by red arrows) in the distal 3<sup>rd</sup> of right leg and foot which appeared isointense to muscle.**



**Figure 5: Sagittal view fat saturated T1WI revealed multiple lesions of varying sizes (as marked by red arrows) in the distal 3<sup>rd</sup> of right leg and foot which showed enhancement post gadolinium contrast.**



**Figure 6: (A) Excision biopsy of the right lateral distal leg swelling was performed. Intra-operatively noted well encapsulated deep red purplish soft tissue mass (marked by black arrow) bounded by the flexor hallucis longus and peroneus brevis anteriorly and Achilles tendon posteriorly. (B) The excised mass measured approximately  $2.3 \times 2.0 \times 2.5 \text{ cm}^3$  in size.**

Patient's excision biopsy wound healed well and the parents were informed regarding the benign nature of the diagnosis based on the HPE results. They were not keen for any further surgical intervention at the moment and decided to defer further surgery as the child's symptom was under control. The patient will be evaluated regularly, and any enlarging painful lesions will be excised as required.

## DISCUSSION

There are two major forms of glomus tumors: solitary or multiple, with solitary more common than the multiple form.<sup>7</sup> Patients with solitary glomus tumor are mostly young adults who presented with painful, red-blue tumor on the extremities with a predilection for subungual sites.<sup>7</sup> The multiple form of glomus tumors is extremely rare and is commonly present in children.<sup>7</sup> Histologically, depending on the predominant component, there are three variants of glomus tumor, namely (1) solid, with poor vasculature and scant smooth muscle component; (2) angiomatoid (glomangioma), with prominent vascular component; and (3) glomangiomyoma, with prominent vascular and smooth muscle components.<sup>8</sup>

Retrospective review by Anakwenze et al reported 22 patients with multiple glomus tumors over the course of

25 years.<sup>9</sup> The mean duration from onset of symptoms until correct diagnosis was long (14.6 years).<sup>9</sup> Most of the patients (90.9%) had involvement of an extremity.<sup>9</sup> An autosomal dominant pattern of inheritance was noted in 13 of 22 patients (59.1%).<sup>9</sup> Hereditary predisposition has been suggested for multiple glomus tumors, however only few familial cases have been reported, and our patient had negative family history as well.<sup>7,9</sup>

Multiple glomus tumors are usually asymptomatic, but painful and painless lesions may be present in the same patients.<sup>7</sup> The classical triad of pain, pinpoint tenderness with blunt palpation, and hypersensitivity to cold for solitary glomus tumor in the hand was not as common for multiple glomus tumor group, it was reported in only 1 out of 22 patients by Anakwenze et al.<sup>9</sup> Thus, the clinical diagnosis is much more problematic and often delayed with multiple consultations prior to correct diagnosis.

Besides the clinical assessment, MRI is a useful investigating tool prior to biopsy for histopathological examination and confirmation of diagnosis. MRI can be used to define the extent of the tumor and its relationship to other anatomical structures. The MRI characteristics for extradigital glomus tumors appear similar to the more established subungual MRI appearance: relatively homogenous iso-to-hypointensity in T1WI, hyper-



intensity in T2WI and strong postcontrast enhancement.<sup>10</sup> Our own case demonstrated MRI findings in congruent with the descriptions.

The therapeutic approach for multiple extradigital glomus tumors is more complicated than solitary one whereby surgical excision is the treatment of choice. Due to their more extensive features, the treatment should be based on patient's symptoms and expectations. If the lesions are asymptomatic and the patient is not troubled by their cosmetic appearance, there is no treatment required.<sup>7</sup> Patients can be followed up periodically for adult patients, and closer monitoring for pediatric patients to look out for disuse hypoplasia secondary to painful limb.

Our patient had hypoplastic leg and foot on the affected side, this could be due to disuse atrophy from the pain. She had multiple consultations for her painful swellings prior to her MRI investigation and referral to our musculoskeletal oncology unit. The delay in diagnosis was due to rarity of her condition and absence of cold hypersensitivity thus did not raise the clinical suspicion of initial treating physicians.

## CONCLUSION

We report a rare case of multiple extradigital glomus tumor in a child with hypoplasia of the affected limb. The clinical diagnosis is much more problematic due to the rare incidents of extradigital glomus tumor and even rarer to see multiple ones. The physicians must include glomus tumors in the differential diagnosis of extradigital lesions so that early diagnosis and treatment could be administered to the patients.

*Funding: No funding sources*

*Conflict of interest: None declared*

*Ethical approval: Not required*

## REFERENCES

1. Schiefer TK, Parker WL, Anakwenze OA, Amadio PC, Inwards CY, Spinner RJ. Extradigital glomus tumors: A 20-year experience. *Mayo Clin Proc.* 2006;81(10):1337-44.
2. Baek HJ, Lee SJ, Cho KH, Choo HJ, Lee SM, Lee YH, et al. Subungual Tumors: Clinicopathologic Correlation with US and MR Imaging Findings. *Radiographics.* 2010;30(6):1621-36.
3. Balaram AK, Hsu AR, Rapp TB, Mehta V, Bindra RR. Large solitary glomus tumor of the wrist involving the radial artery. *Am J Orthop (Belle Mead NJ).* 2014;43(12):567-70.
4. Maxwell GP, Curtis RM, Wilgis EF. Multiple digital glomus tumors. *J Hand Surg Am.* 1979;4(4):363-7.
5. Haiyat S, Akhtar K, Alam F, Siddiqui A. Extradigital Glomus Tumour of Ankle in a Toddler: A Rare Case Report with Unusual Presentation. *J Med Surg Pathol.* 2018;03(02):3-5.
6. Goodman TF. Multiple Glomus Tumors. *Arch Dermatol.* 1971;103(1):11.
7. Iliescu OA, Benea V, Georgescu SR, Rusu A, Manolache L. Multiple glomus tumors. *J Dermatol Case Rep.* 2008;2(2):24-7.
8. Goldblum JR, Weiss SW, Folpe AL. Perivascular tumors. *Enzinger and Weiss's Soft Tissue Tumors.* Chapter 25. 6th ed. Elsevier Health Sciences; 2013: 747-763.
9. Anakwenze OA, Parker WL, Schiefer TK, Inwards CY, Spinner RJ, Amadio PC. Clinical features of multiple glomus tumors. *Dermatologic Surg.* 2008;34(7):884-90.
10. Friske JE, Sharma V, Kolpin SA, Webber NP. Extradigital glomus tumor: a rare etiology for wrist soft tissue mass. *Radiol Case Reports.* 2016;11(3):195-200.

**Cite this article as:** Lim CY, Ng S, Duski S, Chye PC. Multiple extradigital glomus tumors of the ankle and foot with limb hypoplasia in a child: a case report. *Int J Res Orthop* 2019;5:739-43.