

Case Report

Massive complex Baker's cyst treatment with open excision and arthroscopic partial meniscectomy: a case report

Prateek S. Joshi*

Consultant Orthopaedic and Arthroscopy Surgeon, Atharva Orthopaedic Superspeciality Hospital, Nava Vadaj, Ahmedabad, India

Received: 21 May 2019

Accepted: 29 June 2019

***Correspondence:**

Dr. Prateek S. Joshi,

E-mail: prateekortho@yahoo.com

Copyright: © the author(s), publisher and licensee Medip Academy. This is an open-access article distributed under the terms of the Creative Commons Attribution Non-Commercial License, which permits unrestricted non-commercial use, distribution, and reproduction in any medium, provided the original work is properly cited.

ABSTRACT

Baker's cyst is known to be associated with intra articular pathologies such as meniscus tears, chondral lesions, synovitis, synovial plica and cruciate ligament injuries. Complex Baker's cyst excision alone is known to have high chance of recurrence. Combined treatment strategies that addresses intra-articular pathologies with excision of the cyst and closure of the valve, are thought to reduce chances of recurrence of such cysts. We present a case of massive complex Baker's cyst treated with arthroscopic partial medial meniscectomy, synovectomy, open cystectomy and closure of the valve.

Keywords: Popliteal cyst, Baker's cyst, Open excision, Arthroscopy, Partial meniscectomy

INTRODUCTION

Baker's cysts are fluid-filled structures with a synovial lining usually located between the medial head of the gastrocnemius muscle and semimembranosus tendon. Some popliteal cysts communicate with the joint with a valve like mechanism, whereas others communicate freely without such mechanism.¹ There is etiological association between baker's cyst and intra-articular pathologies such as meniscal and anterior cruciate ligament tears, synovial plica, synovitis, and chondral lesions.² Such intra-articular pathologies must be addressed to prevent recurrence of the cyst. Traditionally, open cyst excision alone has been associated with cyst recurrence. More recently, arthroscopic cystectomy has been described but the risk of recurrence persists because complete cyst excision may not be possible with arthroscopy alone. We describe a case of massive complex Baker's cyst measuring 14.3×6.8×4.7 cms in dimension associated with medial meniscus posterior horn complex tear with synovitis in a 58 year old male patient. Combined approach of Arthroscopic partial

medial meniscectomy, synovectomy with open cyst excision and valve closure was used successfully, with no cyst recurrence at 2 years follow up.

CASE REPORT

A 58 year old gentleman presented to us with massive swelling over postero-medial aspect of right knee joint since last 5 years. The swelling appeared spontaneously over period of couple of months and progressed gradually to present size. Initially he was treated conservatively with symptomatic treatment but there was no improvement in his condition. On presentation to us, he complained of painful swelling over back of right knee with difficulty in activities of daily living. Clinically the swelling was located over posterior and postero-medial aspect of right knee. The swelling was well demarcated, fluctuant, non-trans illuminant, firm in consistency and of about 12×5 cm size (Figure 1).

The swelling was firm in full knee extension and soft when the knee was flexed. This finding is known as

Foucher sign. X-ray showed early medial compartment osteoarthritis. MRI scan showed 14.3×6.8×4.7 cm cyst with extensive fibro-vascular synovial thickening and complex tear in posterior horn of medial meniscus (Figure 2). The neurovascular structures were displaced antero-laterally by the cyst.

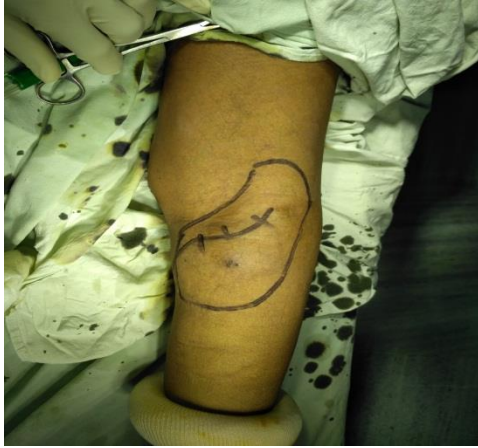

Figure 1: Swelling at posteromedial aspect of right knee.

CT angiography did not show vascular component involving the cyst. However, there was severe atherosclerotic narrowing of bilateral common peroneal arteries. Before proceeding for definitive treatment, biopsy was taken from the cyst for histopathological evaluation, which was consistent with clinical diagnosis of baker's cyst. After ruling out potential differential diagnosis of popliteal fossa swelling such as benign or malignant soft tissue or bony neoplasms, deep vein thrombosis and popliteal artery aneurism we proceeded with definitive surgical treatment.

After taking necessary written informed consent, patient was operated under spinal anesthesia and high tourniquet. First in supine position, standard anterolateral, anteromedial and posteromedial portals were created. Diagnostic arthroscopy was done which confirmed complex posterior horn medial meniscus tear with synovitis involving posteromedial compartment of the knee. Partial medial meniscectomy and synovectomy was done (Figure 3).

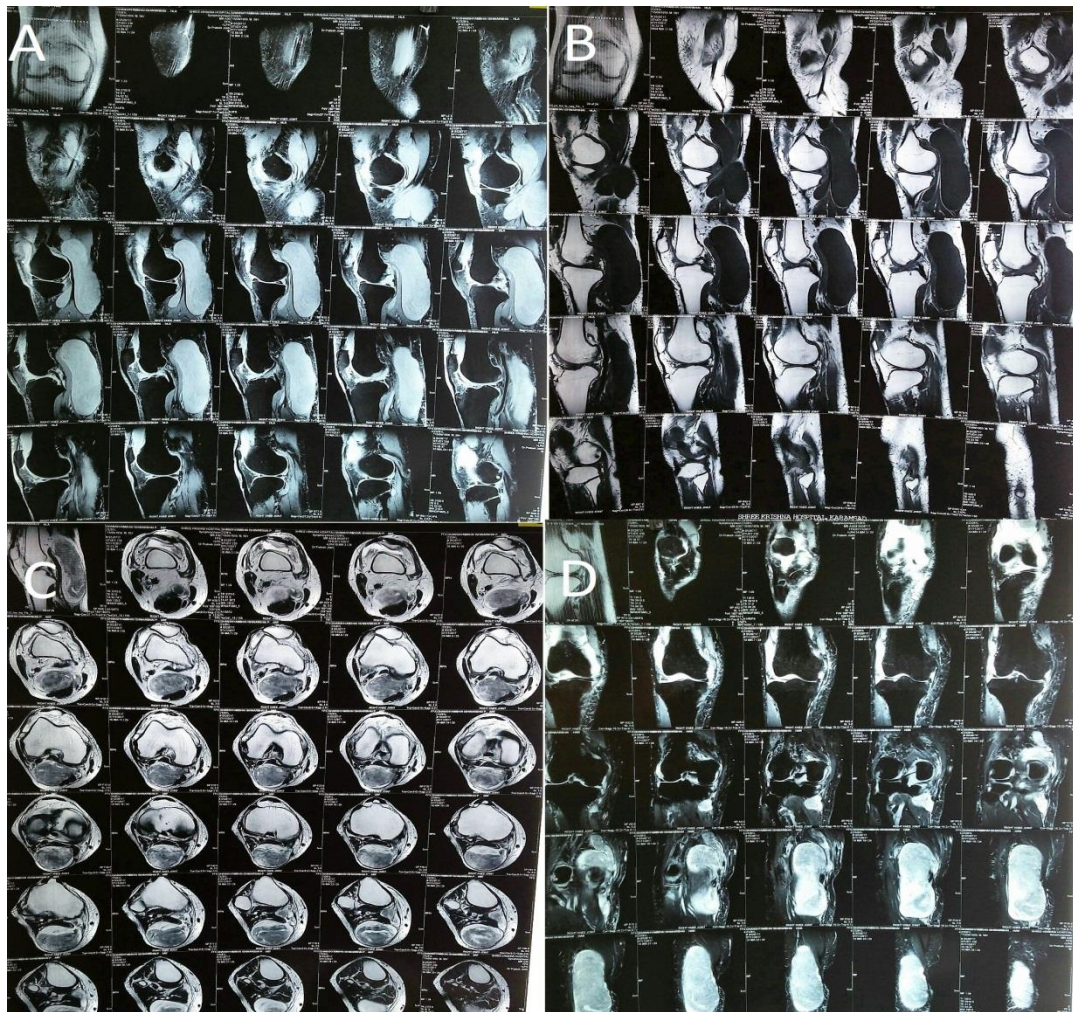

Figure 2 (A-D): MRI scan of right knee showing massive Baker's cyst with posterior horn complex tear.

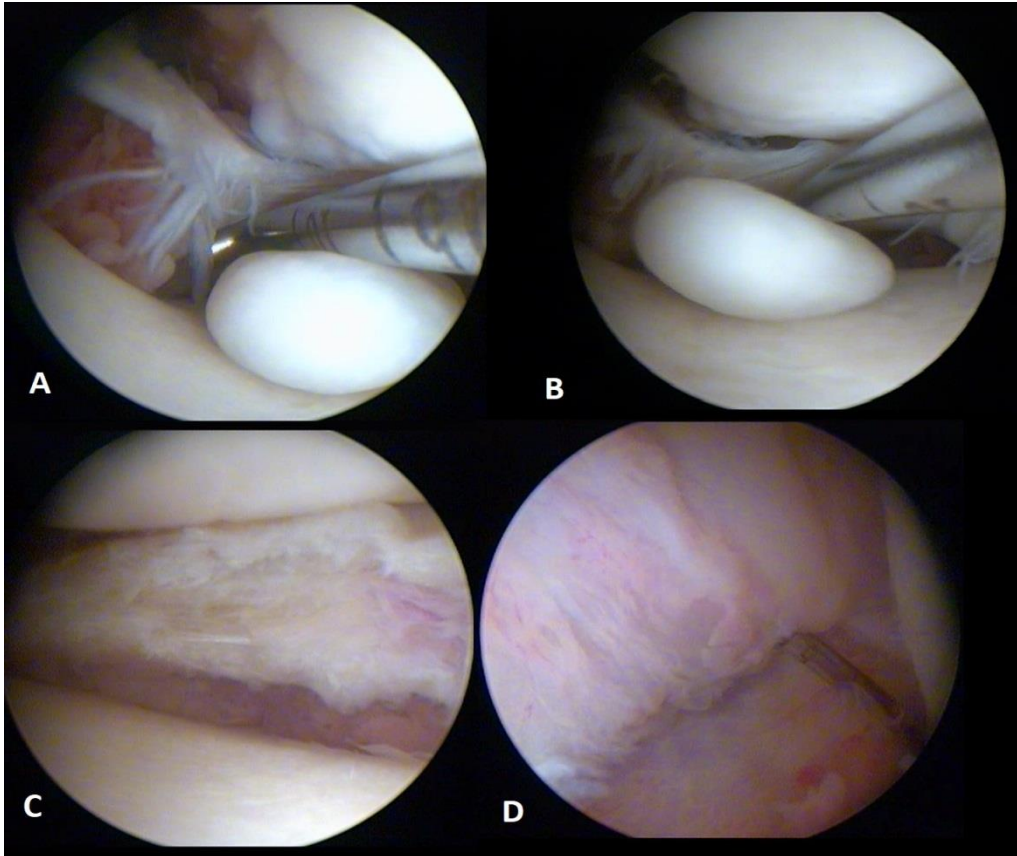


Figure 3: (A and B) Complex medial meniscus posterior horn tear with loose body and synovitis, (C) post partial medial meniscectomy and synovectomy, (D) valve like opening of Baker's cyst.

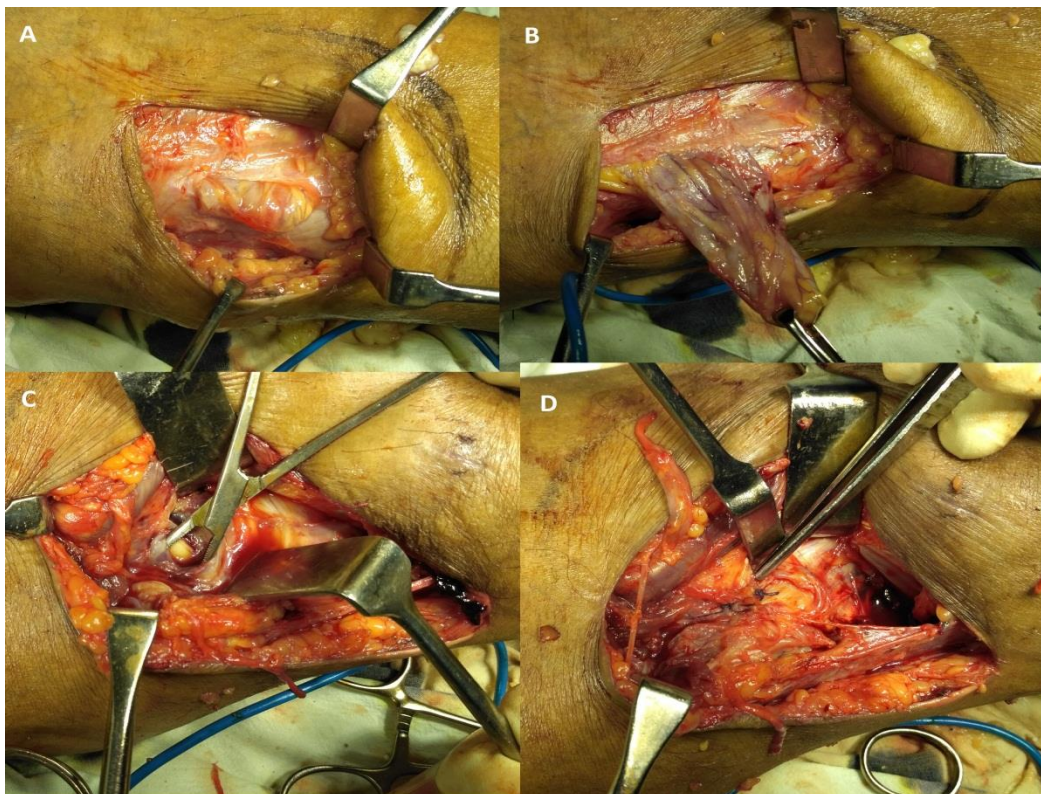


Figure 4: (A) Limited open approach, (B) cyst wall after decompression, (C) valve like communication between cyst and the joint, (D) closure of the valve and supplementation of repair.

Wound was closed and patient was positioned prone and tourniquet was re-inflated. The anatomic landmarks such as posterior crease representing the joint line, the popliteal neurovascular bundle and the popliteal cyst were marked with marking pen. Curvilinear incision of about 7 cm length was made starting from midline at flexor crease superiorly and extending to postero-medial aspect of knee inferiorly. Care was taken not to cross the midline laterally to prevent risk of damaging the neurovascular bundle. The posterior deep fascia is identified with blunt dissection. An incision is made in the fascia in line with the skin incision and the borders of the retinaculum are tagged with sutures for later closure. The cyst was found directly underlying the fascia, between the medial head of the gastrocnemius and the medial hamstring tendons. Blunt dissection delineated the cyst in all direction. In view of massive nature of the cyst, it was decompressed first so that further dissection to remove cyst can be kept to minimum. Serosanguinous fluid with yellowish white cheesy material was extracted. Cyst was removed after separating it from surrounding tissue with blunt dissection. The valve like communication between the cyst and the joint could be identified. It was closed with No. 1 Vicryl suture material (Ethicon, Somerville, NJ) in purse string fashion. Tendon of medial head of gastrocnemius and semimembranosus were used to supplement the repair (Figure 4).

The cyst wall and its contents were sent for histopathological evaluation (Figure 5).

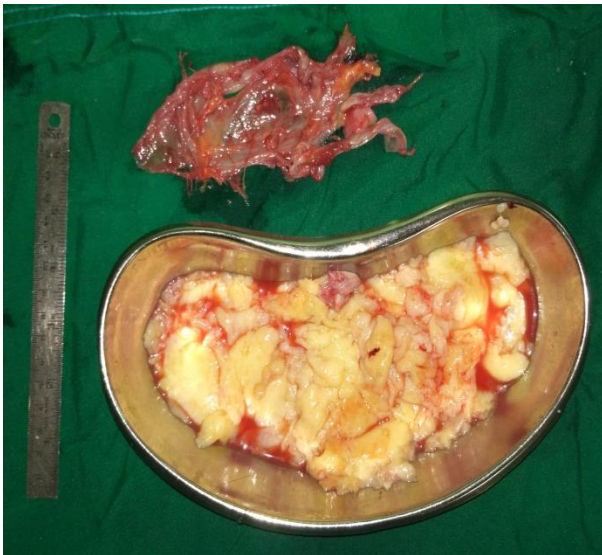


Figure 5: Excised Baker's cyst wall and its content.

He was mobilized from first post-operative day with weight bearing and active knee range of exercises as tolerated by the patient. Histopathological evaluation was consistent with clinical diagnosis of Baker's cyst. Sutures were removed on 12th post-operative day. He was followed up on regular interval. At two years follow up there was no recurrence of cyst.

DISCUSSION

It is believed that pathogenesis of development of Baker's cyst may be associated with intra-articular pathologies. There is high cyst recurrence seen after only excision of the cyst, especially if cyst is complex, large and chronic in nature.¹ There is a study done by Miller et al which describes significant relationship between Baker's cyst and meniscal tears, degenerative arthritis and knee joint effusion based on MRI findings.² Hence, a thorough excision of the cyst in its entirety after addressing intra-articular pathologies with an Arthroscopic procedure appears to be the most effective approach to prevent recurrence of the Baker's cyst.

In literature there are many treatment options described for Baker's cyst, such as ultrasound guided aspiration with intra-articular or intra-cystic steroid injections, sclerotherapy, open surgical cyst excision alone, open surgical cyst excision with closure of valve with or without reinforcing it with surrounding structures, arthroscopic treatment of intraarticular pathology with closure of valve or with excising septa of valve or arthroscopic cystectomy.³⁻⁹ In all these modalities described above there is significant chance of recurrence and failure of surgery, especially in cases with large, chronic, complex Baker's cysts with septation.

There are articles describing treatment with combination of open cyst excision with arthroscopy for intra articular pathologies. Snir et al described such technique with good result in his patients with partial meniscectomy done by arthroscopy.¹⁰

We believe that it's important to classify Baker's cyst into simple or complex one. Simple Baker's cyst has thin cyst wall, homogenous signal intensity on MRI with absence of intra cystic debris or synovial hypertrophy. We believe that a combined arthroscopic and limited open approach for massive complex Baker's cyst is the ideal treatment. Because only with this approach all components affecting the pathogenesis of massive Baker's cyst were addressed. With open approach complete cystectomy with closure of valve is possible and with arthroscopy intra articular pathology can be addressed.

CONCLUSION

Our patient had a massive Baker's cyst for long duration associated with posterior horn medial meniscus complex tear as probable contributing factor apart from early osteoarthritis. We addressed meniscus tear by arthroscopy before going for cyst excision and capsular valve repair using strong absorbable suturing materials such as vicryl with supplementation of repair by reinforcing it with medial head of gastrocnemius and semimembranosus tendon. This combination of treatment is likely to give successful outcome in massive Baker's cyst.

Funding: No funding sources

Conflict of interest: None declared

Ethical approval: Not required

REFERENCES

1. Rauschnig W, Lindgren PG. Popliteal cysts (Baker's cysts) in adults. I. Clinical and roentgenological results of operative excision. *Acta Orthop Scand*. 1979;50:583–91.
2. Miller TT, Staron RB, Koenigsberg T, Levin TL, Feldman F. MR imaging of Baker cysts: association with internal derangement, effusion, and degenerative arthropathy. *Radiology*. 1996;201:247–50.
3. Acebes JC, Sánchez-Pernaute O, Díaz-Oca A, Herrero-Beaumont G. Ultrasonographic assessment of Baker's cysts after intraarticular corticosteroid injection in knee osteoarthritis. *J Clin Ultrasound*. 2006;34:113–7.
4. Németh P, Füzesi K. Sclerosing therapy: an alternative treatment for popliteal cyst in children. *Pediatr Surg Int*. 1990;5:134–5.
5. Childress HM. Popliteal cysts associated with undiagnosed posterior lesions of the medial meniscus. The significance of age in diagnosis and treatment. *J Bone Joint Surg Am*. 1970;52:1487–92.
6. Rauschnig W. Popliteal cysts (Baker's cysts) in adults. II. Capsuloplasty with and without a pedicle graft. *Acta Orthop Scand*. 1980;51(3):547–55.
7. Calvisi V, Lupparelli S, Giuliani P. Arthroscopic all-inside suture of symptomatic Baker's cysts: a technical option for surgical treatment in adults. *Knee Surg Sports Traumatol Arthrosc*. 2007;15(12):1452–60.
8. Ahn JH, Lee SH, Yoo JC, Chang MJ, Park YS. Arthroscopic treatment of popliteal cysts: clinical and magnetic resonance imaging results. *Arthroscopy*. 2010;26:1340–7.
9. Cho JH. Clinical results of direct arthroscopic excision of popliteal cyst using a posteromedial portal. *Knee Surg Relat Res*. 2012;24(4):235–40.
10. Snir N, Hamula M, Wolfson T, Sherman O, Feldman A. Popliteal cyst excision using open posterior approach after arthroscopic partial medial meniscectomy. *Arthrosc Tech*. 2013;2(3):295–8.

Cite this article as: Joshi PS. Massive complex Baker's cyst treatment with open excision and arthroscopic partial meniscectomy: a case report. *Int J Res Orthop* 2019;5:990-4.