

Original Research Article

A prospective study on surgical management of neglected Monteggia fracture in children without annular ligament repair

Satya P. Nayak¹, Chandan K. Panda^{2*}

Department of Orthopaedics, ¹IMS and SUM Medical College, Bhubaneswar, ²MKCG Medical College, Berhampur, Odisha, India

Received: 27 March 2019

Revised: 04 June 2019

Accepted: 06 June 2019

***Correspondence:**

Dr. Chandan K. Panda,

E-mail: pandack88@gmail.com

Copyright: © the author(s), publisher and licensee Medip Academy. This is an open-access article distributed under the terms of the Creative Commons Attribution Non-Commercial License, which permits unrestricted non-commercial use, distribution, and reproduction in any medium, provided the original work is properly cited.

ABSTRACT

Background: Monteggia fracture presenting after 4 weeks of injury termed as neglected monteggia fracture. There are many options for management of this fracture. The present study was planned with objective to assess clinical outcome of patients who were treated with a specific technique of ulnar osteotomy without annular ligament repair.

Methods: This prospective study was conducted in Department of Orthopaedics MKCG Medical College and Hospital, Berhampur from July 2015 to April 2018 where 15 patients of neglected monteggia fracture were operated with specific technique of ulnar osteotomy without annular ligament repair. Participants were followed up and at end point they were evaluated for pain, stability, and disturbance of daily and sporting activities. Function was assessed using elbow performance score. Data collected were analyzed in SPSS (version 16.0).

Results: Mean age of study participants was 7.3 year and male constituted majority (60%). There were 11 children with Bado type I, 3 with type II and one with type III injury. The mean time from initial injury was 8.8 months. All had limited range of movements of forearm and elbow. All patients had regular follow up for 9 months to 24. In 53.3% flexion arc was improved. The mean flexion arc was increased by 20 degree and pronation-supination arc was reduced by 20 degree.

Conclusions: The present study revealed that osteotomy in neglected monteggia fracture brings stability of elbow joint and this surgical management of neglected monteggia fracture without annular ligament reconstruction had good outcome. Annular ligament reconstruction is not always necessary.

Keywords: Missed Monteggia fracture, Flexion arc, Osteotomy, Ligament reconstruction

INTRODUCTION

Monteggia fracture is the fracture of the proximal third of the ulna with anterior dislocation of the head radius.¹ Late presentation of this fracture is a known complication following acute monteggia fracture in children. Monteggia fracture presenting after 4 weeks of injury, termed as neglected monteggia fracture.² This late presentation may be due to improper diagnosis, inadequate radiological film or negligence of patients itself.³⁻⁵ Though there is no clear indications for surgery

in children with neglected monteggia fracture but Progressive valgus deformity of the elbow, limitation of forearm rotation, and pain with strenuous activity are some of the reported indications for surgery.^{4,6} The surgical strategies required to achieve an anatomical reduction become proportionally complex as duration of the fracture increases.^{7,8} Surgical management options are many like ulnar and radial osteotomies, open or closed reduction of the radial head, repair or reconstruction of the annular ligament, temporary fixation of the radial head with a transarticular wire, or some combination of

these techniques. Although many authors recommend a procedure directed at the radio-capitellar joint in order to reduce the radial head.⁹⁻¹³ Hence the present study was planned with the objective to assess the clinical outcome of patients who were treated with a specific technique of ulnar osteotomy without annular ligament repair.

METHODS

Study setting and population

This prospective study was conducted in Department of Orthopaedics MKCG Medical College and Hospital, Berhampur from July 2015 to April 2018. 15 patients of neglected monteggia fracture that is fracture of one month or old post injury fracture were included in this study. Patient had previous pathology around the concerned elbow joint were excluded from study. All cases were followed up prospectively in the department. Informed consent was taken from patients and ethical clearance was done from the IEC of institution.

Procedure

All operative procedures were performed and under general anaesthesia by same surgeons. The ulna shaft was approached directly and an osteotomy was performed either at the proximal metaphysis or at the centre of rotation of angulation. The osteotomy site was distracted and angulated to overcorrect the ulnar deformity. The mean angulation was 18.8 (range 10–25), and the mean distraction was 8.5 (range 3–18) mm. The degree of angulation was determined by evaluation of the reduction of the radial head under image-intensification, in all combinations of full flexion, extension, pronation and supination in both lateral and antero-posterior projections. In case 1, however, the incision was extended proximally via a Kocher approach to observe the position of the radial head in the radio-capitellar joint under direct vision. In five patients the ulna was fixed with a plate and screws, and in one patient with an elastic nail (case 5). Allograft bone graft substitute was utilized in all cases. It was not necessary to perform ligament reconstruction, radial osteotomy, temporary transarticular

radio-capitellar wire stabilization, or neurolysis in any of the patients. A long arm plaster splint was applied for 2 weeks with the elbow in 90 of flexion and the forearm in neutral rotation. At that point the children were encouraged to use the elbow as tolerated, and no formal physiotherapy was advised. At final follow-up, patients were questioned about pain, stability, and disturbance of daily and sporting activities. Physical examination included evaluation of elbow and forearm range of motion. Function was assessed using the elbow performance score.

Data analysis

Data collected were analyzed in SPSS (version 16.0) quantitative data represented as number, percentage and mean with standard deviation. P value less than 0.05 was taken as statistically significant.

RESULTS

There were total 15 patients who were included in the study after qualifying inclusion criteria. Mean age of study participants’ was 7.3 year which ranged from 4.8 years to 9.2 years. Male constituted majority (60%) and only 40% were female. Bado classification was used to describe monteggia fracture. Bado classification based on the direction of the radial head in fracture; in type I the head is anterior, type II is posterior, type III is lateral and In type IV there is a dislocation of the radial head associated with a fracture of both the radius and ulna.¹ There were 11 children with Bado type I, 3 children with type II and only one child was with Bado type III injury. Out of 15 patients, 8 had fracture in right side elbow and rest 7 had on left side. The mean time from initial injury was 8.8 months. All had limited range of movements of forearm and elbow and pain. None of them had complained of neurological involvement. On preoperative radiological evaluation the direction of dislocation, carrying angle, head–neck ratio and any abnormal bony architecture were documented. Patient’s preoperative data are summarized in Table 1. All patients had regular follow up for 9 months to 24 months. it was depicted in Figure 1.

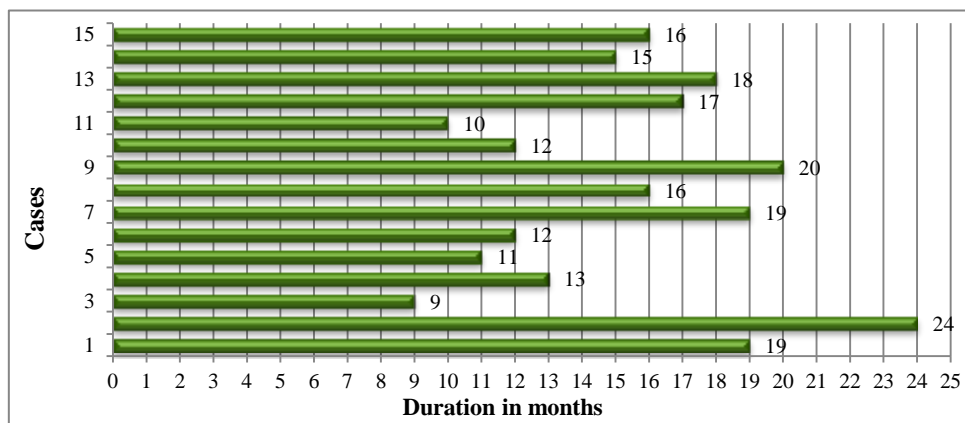


Figure 1: Bar diagram showing duration of follow up in months.

Table 1: Clinical details of study participants in the study (n=15).

Variable	
Age in years (Mean±SD)	7.3±1.32
Gender	N (%)
Male	9 (60)
Female	6 (40)
Classification of fracture (Bado type)	
Type I	11 (73.3)
Type II	3 (20)
Type III	1 (6.7)
Elbow involvement	
Left side	6 (40)
Right side	9 (60)
Duration from initial injury in months (Mean±SD)	8.8±3.3

Table 2: Elbow function of study participants before and after surgery (n=15).

Case	Normal unaffected elbow		Affected elbow					
	Flex/n/ext	Pro/n/sup	Flex/neu/ext			Pro/neu/sup		
			Pre-op	Post-op	Change	Pre-op	Post-op	Change
1	135/0/5	90/0/80	120/0/5	130/0/0	5	90/0/80	90/0/80	0
2	135/0/0	90/0/90	130/0/5	120/0/0	-15	90/0/90	80/0/80	-20
3	130/0/5	80/0/90	130/0/5	130/0/0	-5	80/0/80	90/0/90	20
4	135/0/0	80/0/90	120/0/5	130/0/5	10	90/0/80	90/0/80	0
5	135/0/5	90/0/80	120/0/5	130/0/0	5	90/0/80	80/0/80	-10
6	140/0/5	80/0/90	120/0/5	135/0/0	10	90/0/80	80/0/80	-10
7	130/0/5	90/0/80	120/0/0	130/0/0	10	80/0/80	80/0/80	0
8	135/0/0	90/0/80	130/0/5	130/0/5	0	80/0/90	70/0/80	-20
9	140/0/0	90/0/80	130/0/0	110/0/0	-20	90/0/80	80/0/80	-10
10	140/0/5	90/0/90	120/0/5	130/0/0	5	70/0/80	90/0/80	20
11	135/0/5	80/0/90	120/0/0	135/0/5	20	80/0/80	90/0/80	10
12	130/0/0	80/0/90	130/0/0	135/0/0	5	80/0/80	80/0/80	0
13	140/0/0	90/0/90	135/0/0	130/0/0	-5	80/0/70	80/0/80	10
14	135/0/0	80/0/90	130/0/5	130/0/0	-5	80/0/90	80/0/90	0
15	130/0/0	90/0/80	130/0/0	130/0/0	0	90/0/80	80/0/80	-10

* Negative mark indicates reduction in range of motion.

Table 2 describes the elbow function of participants before and after surgery. In most of the cases (53.3%) the flexion arc was improved. The mean flexion arc was increased by 20 degree. However the pronation-supination arc was reduced by 20 degree. There was no complain of activity related to pain or disability in daily function after surgery.

DISCUSSION

Chronic radial head dislocation due to a missed Monteggia fracture is a recurrent problem. Inadequate or no primary treatment at the time of injury is the main cause of this type of deformity. The principle cause for the dislocation is the closed ring-like anatomy of the radius and ulna along with the interosseous membrane and the annular ligament. Disruption and malunion of the ulna leads to shortening and angulation of one arm of the ring. ¹⁴ The problems associated with neglected radio-

ulnar dislocation after a Monteggia fracture–dislocation includes loss of forearm rotation, cubitus valgus, elbow instability, pain, degenerative arthritis, subluxation of the distal radioulnar joint and late neuropathy. ¹⁵

The type of surgery for missed monteggia fracture varies and there is no complete unanimity regarding treatment of this type of fracture in children. In the present study 15 patients were studied who had ulnar osteotomy without annular ligament reconstruction for neglected monteggia fracture. The youngest child was 57 months old and majorities (60%) were male children. The maximum duration from initial injury was 16 months. after surgery, iIn most of the cases the flexion arc was improved. The mean flexion arc was increased by 20 degree. However the pronation-supination arc was reduced by 20 degree. There was no complaining of activity related to pain or disability in daily function after surgery.

Some reported of using ulnar distraction with external fixator to effect radial head reduction with opening the joint.^{8,16} In these cases ulnar lengthening and angulations maintain stability of the radial head. In the study by Hasler et al., 15 cases of neglected monteggia fracture were managed by external fixation of the ulna osteotomy with open reduction of the radiocapitellar joint and no one had annular ligament reconstruction. He reported no displacement of radial head.¹⁷ Similarly Inoue et al. also found ulnar angulation with simple osteotomy.⁴

Annular ligament reconstruction can present with complications. Gyr et al. in their study, studied 15 children who were underwent annular ligament reconstruction and later had some limitation of forearm rotation and some had radial head re subluxation.¹⁸ Some other authors also reported restriction of forearm rotation, nerve injury, myositis ossificans and re-displacement of radial head.^{5,19,20} Open reduction of radial head and reconstruction of annular ligament combined with ulnar osteotomy by Rodgers et al. showed unpredictable results in his five of seven cases.⁵

Nakamura et al. and David-West et al. stress annular ligament reconstruction in all cases.^{14,21} Bhasker in his study, 5 cases were managed with annular ligament reconstruction and 6 cases without ligament reconstruction. All children had limitations of forearm rotation. However the limitation of elbow motion did not affect any function. Their study stresses the importance of ailment of the ulna in restoring radial head stability and that annular ligament reconstruction is not always necessary.²²

Megahed et al in their study had done V shaped ulnar osteotomy with annular ligament reconstruction in neglected monteggia fracture dislocation in children. In their study they also found increase in flexion of elbow (increased by 3 degree) and slight decrease in rotation of the forearm (decreased by 4 degree). They concluded that V-shaped corrective ulnar osteotomy technique without bone grafting is a technically simple, less demanding procedure, which achieves lengthening and angulation of the ulna simultaneously and reduces the radial head and with annular ligament reconstruction will suffice in most cases of missed monteggia fractures.²³ Devnani et al got good results without repairing or reconstructing the annular ligament in missed monteggia fracture dislocation in children. At the end of follow up, he reported no deformity or subluxated in radial head, nearly full flexion at elbow and full supination with restricted pronation in forearm.²⁴

Longer follow up with more sample size study is needed to arrive at a definite conclusion. However this study will facilitate further study based on its results.

CONCLUSION

Treatment of missed monteggia fracture in children is a therapeutic challenge. Though there are various surgical

options, the outcomes of these multiple techniques are still uncertain. The present study revealed that osteotomy in neglected monteggia fracture brings stability of elbow joint and this surgical management of neglected monteggia fracture without annular ligament reconstruction had good outcome. Hence osteotomy without annular ligament repair is a good option for the management of the missed monteggia fracture in children.

ACKNOWLEDGEMENTS

The authors express their gratitude towards all study participants for their valuable time. Authors would like to extend their gratitude to the staffs of the department of Orthopaedics, MKCG Medical College, Berhampur for their contributions and technical supports.

Funding: No funding sources

Conflict of interest: None declared

Ethical approval: The study was approved by the institutional ethics committee

REFERENCES

1. Bado JL. The Monteggia lesion. *Clin Orthop Relat Res.* 1967;50:71–86.
2. Goh SH. Monteggia fracture-dislocation with bowing of the ulna: a pitfall for the unwary emergency physician. *Eur J Emerg Med.* 2008;15:281-2.
3. Chen WS. Late neuropathy in chronic dislocation of the radial head. Report of two cases. *Acta Orthop Scand.* 1992;63:343-4.
4. Inoue G, Shionoya K. Corrective ulnar osteotomy for malunited anterior Monteggia lesions in children. 12 patients followed for 1-12 years. *Acta Orthop Scand.* 1998;69:73-6.
5. Rodgers WB, Waters PM, Hall JE. Chronic Monteggia lesions in children. Complications and results of reconstruction. *J Bone Joint Surg Am.* 1996;78:1322-9.
6. Oner FC, Diepstraten AF. Treatment of chronic post-traumatic dislocation of the radial head in children. *J Bone Joint Surg Br.* 1993;75(4):577–81.
7. Rodgers WB, Waters PM, Hall JE. Chronic Monteggia lesions in children. Complications and results of reconstruction. *J Bone Joint Surg Am.* 1996;78(9):1322-9.
8. Exner GU. Missed chronic anterior Monteggia lesion. Closed reduction by gradual lengthening and angulation of the ulna. *J Bone Joint Surg Br.* 2001;83(4):547-50.
9. Hirayama T, Takemitsu Y, Yagihara K, Mikita A. Operation for chronic dislocation of the radial head in children. Reduction by osteotomy of the ulna. *J Bone Joint Surg Br.* 1987;69(4):639-42.
10. Degreef I, De Smet L. Missed radial head dislocations in children associated with ulnar

- deformation treatment by open reduction and ulnar osteotomy. *J Orthop Trauma.* 2004;18(6):375-8.
11. Eygendaal D, Hillen RJ. Open reduction and corrective ulnarosteotomy for missed radial head dislocations in children. *Strategies Trauma Limb Reconstr.* 2007;2(1):31-4.
 12. Läderrmann A, Ceroni D, Lefèvre Y, De Rosa V, De Coulon G, Kaelin A. Surgical treatment of missed Monteggia lesions in children. *J Child Orthop.* 2007;1(4):237-42.
 13. Belangero WD, Livani B, Zogaib RK. Treatment of chronic radial head dislocations in children. *Int Orthop.* 2007;31(2):151-4.
 14. Nakamura K, Hirachi K, Uchiyama S, Takahara M, Minami A, Imaeda T. Term clinical and radiographic outcomes after open reduction for missed monteggia fracture-dislocations in children. *J Bone Joint Surg Am.* 2009;91:1394-404.
 15. Lloyd-Roberts GC, Bucknill TM. Anterior dislocation of the radial whead in children: Aetiology, natural history and management. *J Bone Joint Surg Br.* 1997;59:402-27.
 16. Gicquel P, De Billy B, Karger C, Maximin MC, Clavert JM. Treatment of neglected Monteggia's fracture by ulnar lengthening using Ilizarov technique. *Rev Chir Orthop Reparatrice Appar Mot.* 2000;86:844-7.
 17. Hasler CC, Von Laer L, Hell AK. Open reduction, ulnar osteotomy and external fixation for chronic anterior dislocation of the radial head. *J Bone Joint Surg Br.* 2005;87:87-94.
 18. Gyr BM, Stevens PM, Smith JT. Chronic Monteggia fractures in children: Outcome after treatment with the Bell-Tawse procedure. *J Pediatr Orthop B.* 2004;13:402-6.
 19. Osamura N, Ikeda K, Hagiwara N, Tomita K. Posterior interosseous nerve injury complicating ulnar osteotomy for a missed Monteggia fracture. *Scand J Plast Reconstr Surg Hand Surg.* 2004;38:376-8.
 20. De Boeck H. Radial neck osteolysis after annular ligament reconstruction: A case report. *Clin Orthop Relat Res.* 1997;342:94-8.
 21. David-West KS, Wilson NI, Sherlock DA, Bennet GC. Missed monteggia injuries. *Injury.* 2005;36:1206-1209.
 22. Bhasker A. Missed Monteggia fracture in children: is annular ligament reconstruction always required? *Indian J Orthop.* 2017;12:389-95
 23. Megahed RM, Elalfy TA, Abdelwahab AM. V-Shaped Corrective Ulnar Osteotomy in Neglected Monteggia Fracture Dislocation in Children. *Orthop Muscular Syst.* 2017;6:229.
 24. Devnani AS. Missed monteggia fracture dislocation in children. *Injury.* 1997;28:131-3.

Cite this article as: Nayak SP, Panda CK. A prospective study on surgical management of neglected Montaggia fracture in children without annular ligament repair. *Int J Res Orthop* 2019;5:718-22.