

## Original Research Article

# Study of percutaneous K wire fixation in supracondylar fracture of humerus in children

Putappa Gopinath, Sabneet Singh\*, Abdul Ravooof

Adichunchanagiri Institute of Medical Sciences, Mandya, B G Nagara, Karnataka, India

**Received:** 16 March 2019

**Revised:** 11 April 2019

**Accepted:** 12 April 2019

**\*Correspondence:**

Dr. Sabneet Singh,

E-mail: [sabneetsingh1990@gmail.com](mailto:sabneetsingh1990@gmail.com)

**Copyright:** © the author(s), publisher and licensee Medip Academy. This is an open-access article distributed under the terms of the Creative Commons Attribution Non-Commercial License, which permits unrestricted non-commercial use, distribution, and reproduction in any medium, provided the original work is properly cited.

### ABSTRACT

**Background:** Closed reduction is difficult not only to achieve but also to maintain because of the thinness of bone of the distal humerus between the coronoid and olecranon where most supracondylar fractures occurs. For this reason percutaneous pinning techniques have become the treatment of choice for most supracondylar fractures. By this procedure even the displaced and rotated fracture can be treated successfully with minimal incidence of complications. The purpose of this study is to determine the efficacy of management of displaced supracondylar fractures using closed reduction with percutaneous K-wire pinning and to analyze the results, loss of carrying angle, and loss of motion with incidence of complications.

**Methods:** 20 cases of displaced supracondylar fractures in children aged between 5 and 12 years were treated by closed reduction and percutaneous pinning and were studied prospectively for functional outcome. 8 cases were treated with crossed pinning. 11 cases were treated with 3K wire fixation and 1 with lateral pinning.

**Results:** 85% of the patients observed excellent results. 15% of the patients observed fair results. Of the cases treated by 3K wire fixation 55% had excellent results and cases with crossed pinning 40% had good results and 5% had poor results. All the patients treated with lateral pinning had excellent results.

**Conclusions:** The results obtained in this study shows that anatomical reduction by closed method and stabilization with K-wire fixation is the first treatment of choice for displaced supracondylar fractures.

**Keywords:** Children, Humerus, K-wire, Supracondylar fracture

### INTRODUCTION

Supra-condylar fracture humerus (SCFH) in children account for 50% to 70% of all elbow fractures and are seen most frequently in children between the ages of 3 and 10 years the high incidence of residual deformity and the potential for neurovascular complications make supracondylar humeral fractures a serious injury.<sup>1</sup>

Many methods have been proposed for the treatment of displaced supracondylar fractures of the humerus in

children, such as closed reduction and plaster of Paris slab application, skin traction, overhead skeletal traction, open reduction and internal fixation, and closed reduction and percutaneous pin fixation.<sup>2</sup>

K-wire fixation in type 2 and type 3 SCFH gives good results. It is done either through lateral entry or one medial and one lateral entry. This study is to evaluate the clinical, radiological and functional outcome following closed reduction and percutaneous pinning of widely displaced SCFH.

## METHODS

### Study design and sampling

A prospective study conducted on 20 patients from both rural and urban area. Patients admitted in orthopedic department of Adichunchanagiri Institute of Medical Sciences, BG Nagara from January 2017 to January 2018.

### Study subjects

They were investigated and operated under general anesthesia. The crossed pin fixation was done in 8 patients and 11 cases were operated with 3 K wire fixation and remaining 1 was treated with lateral K wire fixation. Of which 6 were type II, 5 of them underwent 2 K-wire crossed pinning configuration and 1 of them underwent 2 lateral pinning configuration. Of the 14 patients, who had type III fracture, 11 of them underwent 3 K-wire pinning and 3 of them underwent 2 K-wire crossed pinning configuration. All patients have been followed for at least 1 year.

### Technique of k wire fixation

This procedure is used for both type II and type III fractures after preoperative evaluation. Under general anesthesia and under C arm fluoroscopy, closed reduction is done. Both anteroposterior and lateral images must confirm good reduction which is very important for a good outcome. The K wires used for fixation are of 1.5 mm or 2 mm diameter. After giving a small nick in the skin, the medial and lateral condyles were identified under image intensifier. The direction and length of k wire was checked. Stability of the fracture was checked under C-arm image intensifier. When using crossed k wire, medial k wire fixation carries the risk of ulnar nerve compression or injury, so care was taken to avoid that. After the fixation, the elbow was moved through its full range.<sup>14</sup>

Above-elbow plater of Paris slab is given after properly padding the arm and forearm. The first 12 hours is critical for observing the radial pulse, sensations and finger movements. The limb is elevated and a full range of movements at metacarpo-phalangeal and inter phalangeal joints are advised. The elbow movement is started after the PoP slab was removed at the end of 3 weeks. Patients were followed up in 2nd and 3rd postoperative weeks. X rays were taken to see the callus formation which would be better seen in lateral views. Physiotherapy was continued after slab removal and followed for any swelling, any pin track infection. Elbow range of movements and the carrying angle were observed.

### Sampling method: Random sampling

Age group: 5-12 yrs, type 3 Gartland classification and children with unstable displaced or irreducible type 2 (Gartland classification) fractures were included in the

study and patients with undisplaced fractures, pathological fractures and comminuted type 3C (Gustillo Anderson classification) open fractures were excluded from the study.

### Statistical analysis

Descriptive statistics like frequencies, percentages, mean and standard deviation. Chi square test was used compare categorical data.  $P < 0.05$  was considered statistically significant. Data entry was done in MS Excel and analysis was done in IBM SPSS v 2.0.

### Ethical approval

Patients were explained the purpose of the study and informed consent was obtained. Those refusing to consent were excluded from the study. The study was approved by Institutional ethical committee Adichunchanagiri Institute of Medical Sciences, B.G Nagara.

## RESULTS

This is a prospective study, conducted on 20 cases of supracondylar fracture (type II and type III), who underwent open/closed reduction with K-wire fixation between January 2017 and January 2018, in Adichunchanagiri Institute of Medical Sciences. The following observations were made.

### Demographic characteristics of the patients

The age of patients ranged from 5-12 years. The average age was 7.35 years.

**Table 1: Age distribution.**

Age (years)	Number of patients (%)
5-8	13 (65)
9-12	7 (35)
<b>Total</b>	<b>20 (100)</b>

The  $\chi^2$  value was 7.4 and the p value was 0.025, which is significant.

Our Department of Orthopedics conducted this study from January 2017 to January 2018 with a follow up of all cases for at least 1 year. The total numbers of SCFH were 20. Of the total number, type II are 6 and type III are 14.

Based on the Gartland's classification, 6 patients had Type II fracture and 14 of them had Type III fracture.

There were a total of 20 children operated for SCFH in this study. 15 were male and 5 were female children. Left elbow was more involved 15 patients i.e., 75% and left elbow in 5 patients i.e., 25%. The closed supracondylar fractures were 44 and open supracondylar fractures were 8.

**Table 2: Types of fracture**

Type of fracture	Number of patients (%)
<b>Type II</b>	6 (30)
<b>Type III</b>	14 (70)
<b>Total</b>	20 (100)

The  $\chi^2$  value is 0.317, p value is 0.573 and degree of freedom (df) = 1 which makes it insignificant.

**Table 3: Sex distribution.**

Sex	Number of patients (%)
<b>Male</b>	15 (75)
<b>Female</b>	5 (25)
<b>Total</b>	20 (100)

The  $\chi^2$  value is 4.356 and the p value is 0.037, making it significant.

Most of the injuries occurred during playing and fall from height i.e., 16 children. Remaining 4 are due to road traffic accidents. Out of the 14 cases who had Type III fracture, 12 of them had posteromedial displacement and 2 of them had posterolateral displacement.

Preoperative injuries were seen in 3 patients, 1 patient had radial nerve injury and 1 patient had medial nerve injury. In all these cases, nerve functions improved by 6-8 weeks. One patient had distal radius fracture, which improved following closed reduction and pinning.

Of the 20 cases, 11 patients underwent closed reduction, of which 6 belonged to Type II and 5 belonged to Type III fractures. All the 9 patients who underwent open reduction, had Type III fractures.

**Table 4: Pinning method.**

Wiring	2-cross wire	2 lateral	3 K-wire	Total
	N (%)	N (%)	N (%)	N (%)
<b>Type II</b>	5 (83.3)	1 (16.7)	-	6 (100)
<b>Type III</b>	3 (21.4)	-	11 (78.6)	14 (100)

The  $\chi^2$  value is 11.071 and the p value is 0.004, making this result significant.

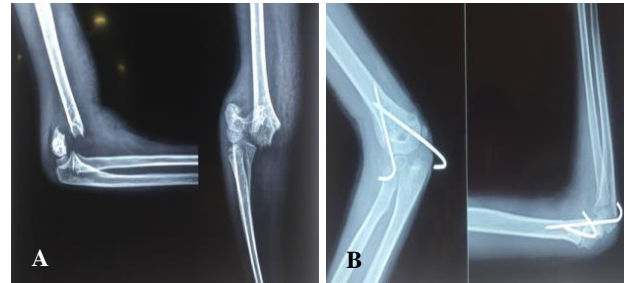
Of the 20 cases, 8 of them underwent 2 cross wired pinning, 1 of them underwent lateral pinning and 11 of them underwent 3 K-wire pinning. Of the 6 patients who had type II fracture, 5 of them underwent 2 K-wire crossed pinning configuration and 1 of them underwent 2 lateral pinning configuration. Of the 14 patients, who had type III fracture, 11 of them underwent 3 K-wire pinning and 3 of them underwent 2 K-wire crossed pinning configuration

**Complications observed in our study**

One patient developed pin tract infection, which was recognized by the presence of hypertrophic granulation tissue, which healed with antibiotic therapy and 1 patient developed cubitus varus deformity of right hand, but

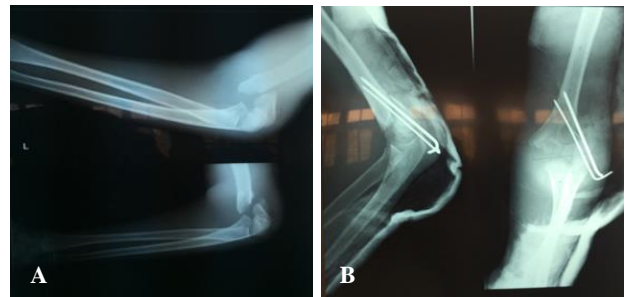
maintained good functional movement. During the study and during follow up, the problems of vascular injury, compartment syndrome, myositis ossificans and non-union were not of much concern.

**Case series 1**



**Figure 1 (A and B): Pre-op and post-op.**

**Case series 2**



**Figure 2 (A and B): Pre-op and post-op.**

**DISCUSSION**

Closed reduction and k wire fixation of supra condylar fracture in children is a sound and effective technique especially for type 2 and type 3 fractures.<sup>5-8</sup> The type 1 fractures are safely treated with immobilization in plaster of Paris. In total 20 patients who were fixed with k wires, excellent results in 85% patients, good results in 10% patients & fair results in 5% patients were obtained. Of the 20 cases, according to Flynn’s criteria 80% patients had limitation of 0-5 degree, 15% patients had 5-10 degree, 5% patient had 10-15 degree and no patient had limitation of movement >15 degree.

Deep pin tract infection was detected in 1 patient in which K wire was removed after 3 weeks. Excellent and good results have been seen in our study.

Cubitus varus deformities remain a common complication if it is not treated by k-wire fixation. In other technique like open reduction and internal fixation the results are varied with incidence of varus deformity ranging from 3 to 30%. Persistent elbow stiffness after open reduction is also reported.<sup>7-9</sup> Percutaneous pinning after closed reduction has got an edge over other techniques. Immediate fixation of these fractures reduces

the hospital stay. This technique provide anatomic and stable fixation. This minimizes the risk of compartment syndrome and increases the circulation. K-wire fixation has its own rare disadvantages, complications like ulnar nerve injury, wire extrusion and pin tract infection and heterotrophic ossification have been reported.<sup>10-13</sup> These complications have been reported in a very few cases of our study.

The mean Baumann angle loss in medio-lateral pin fixation group and lateral pin fixation group, was 4.4 and 4.6 respectively. Analysis of the angle loss did not show much difference between the 2 groups. The 3rd pin from lateral side in mediolateral group was not necessary and the fixation with medio-lateral and lateral fixation was stable. The loss of fixation was slightly more in number in 2 lateral pin fixation method. The SCFH is fixed in type 2 and 3 fractures which facilitates good stable fixation, early union and lessens the displacement of the distal fragment. This technique and k wire fixation is associated with good function and less morbidity, and children can freely move the shoulder and fingers. Good reduction and stable fixation is aimed for, in all cases.

Devakumaran advocated primary open reduction and K-wire fixation and obtained 93% excellent a 6.7% good results. He advised minimal tissue trauma, and early mobilisation for better results.<sup>12</sup>

As compared to the study made by Devakumaran obtained 93% excellent results and 6.7% good results, in our study we obtained excellent results in 85% of cases and good results in 10% with lateral percutaneous pinning.

## CONCLUSION

The treatment of type 2 and 3 SCFH by closed reduction and percutaneous pin fixation has given consistently good results, compared to closed reduction and PoP casting. With closed reduction and POP casting it is difficult to maintain reduction; whereas open reduction and k wire fixation and other methods of fixation are fraught with risks of excess callus/myositis and deep infection of the wound which results in delay in starting the physiotherapy and getting a good range of movements. Adequate fixation is achieved with both lateral/crossed k wire fixation. The both lateral pin fixation is found to be a relatively safe and easier method compared to crossed k-wire fixation. In crossed wire fixation iatrogenic ulnar nerve injuries are likely if due care is not taken. The pin fixation from lateral side has the advantage of avoiding ulnar nerve injury but the fixation may be relatively less stable and some authors reported that mediolateral entry provides greater torsional rigidity than lateral entry method does. The main advantage and strength of this mediolateral fixation is the divergence of pins in different columns. The use of two pins laterally was preferred to reduce the risk of infection and to avoid ulnar nerve palsy. According to Skaggs et al the use of lateral-entry

pins alone was effective for even the most unstable supracondylar humeral fractures.<sup>3,4</sup> From the present study it could be concluded that closed reduction and percutaneous fixation is a sound and effective technique for treatment of displaced Supracondylar fractures in children.

*Funding: No funding sources*

*Conflict of interest: None declared*

*Ethical approval: The study was approved by the institutional ethics committee of Adichunchanagiri Institute of Medical Sciences*

## REFERENCES

1. John AH. Tachdjian's pediatric orthopaedics. 4th ed. Philadelphia: Saunders; 2008: 2451-2476.
2. Pirone AM. Management of displaced extension-type supracondylar fractures of the humerus in children. *J Bone Joint Surg.* 1988;70;641-50.
3. Skaggs DL, Cluck MW, Mostofi A, Flynn JM, Kay RM. Lateral-entry pin fixation in the management of supracondylar fractures of humerus in children. *J Bone Joint Surg Am.* 2004;86:702-7.
4. Skaggs DL, Hale JM, Bassett J, Kaminsky C, Kay RM, Tolo VT. Operative treatment of supracondylar fractures of humerus in children. The consequences of pin placement. *J Bone Joint Surg Am.* 2001;83:735-40.
5. Gordon JE, Patton CM, Luhmann SJ, Bassett GS, Schoenecker PL. Fracture stability after pinning of displaced supracondylar fractures of humerus in children. *J Pediatr Orthop.* 2001;21:313-8.
6. Karapinar L, Ozturk H, Altay T, Kose B. Closed reduction and percutaneous pinning with three Kirschner wires in children with type III displaced supracondylar fractures of the humerus. *Acta Orthop Traumatol Turc.* 2005;39:23-9.
7. Reynolds RA, Jackson H. Concept of treatment in supracondylar humeral fractures. *Injury.* 2005;36(1):51-6.
8. Ippolito E, Caterini R, Scola E. supracondylar fractures of the humerus in children. Analysis at maturity of fifty-three patients treated conservatively. *J Bone Joint Surg Am.* 1986;68:333-44.
9. Devnani AS. Late presentation of supracondylar fracture of the humerus in Children. *Clin Orthop Relat Res.* 2005: 36-41.
10. Royce RO, Dutkowsky JP, Kasser JR, Rand FR. Neurologic complications after K-wire fixation of supracondylar humerus fractures in children. *J Pediatr Orthop.* 1991;11:191-4.
11. Green DW, Widmann RF, Frank JS, Gardner MJ. Low incidence of ulnar nerve injury with crossed pin placement for paediatric supracondylar humerus fractures using a mini-open technique. *J Orthop Trauma.* 2005;19:158-63.

12. Rasool MN. Ulnar nerve injury after K-wire fixation of Supracondylar humerus fractures in children. *J Pediatr Orthop.* 1998;18:686–90.
13. Devkumaran KC. Displaced Supracondylar fractures of humerus in children, primary open reduction and fixation with K-wires. *IJO.* 1985;19:120-5.
14. Rao SY, Chakravorthy M, Yadagiri. Percutaneous K Wire Fixation in SCFH. *J Med Allied Sci.* 2015;5(1):6-9.

**Cite this article as:** Gopinath P, Singh S, Ravooof A. Study of percutaneous K wire fixation in supracondylar fracture of humerus in children. *Int J Res Orthop* 2019;5:427-31.