

Original Research Article

Management of boxers fracture with single antegrade bent K-wire

Mohammed Sadiq, Syed Azher Hussain*

Department of Orthopaedics, ESIC Medical College, Gulbarga, Karnataka, India

Received: 23 February 2019

Revised: 07 March 2019

Accepted: 08 March 2019

***Correspondence:**

Dr. Syed Azher Hussain,

E-mail: drazherhussainn@gmail.com

Copyright: © the author(s), publisher and licensee Medip Academy. This is an open-access article distributed under the terms of the Creative Commons Attribution Non-Commercial License, which permits unrestricted non-commercial use, distribution, and reproduction in any medium, provided the original work is properly cited.

ABSTRACT

Background: Fractures of the neck of fifth metacarpal are commonly encountered in orthopaedic practice. Management of these fractures is a debatable topic with treatment varying from conservative management to surgical fixation. In our study we used a pre-bent k wire in antegrade fashion to achieve fracture fixation. We found that pre-bent K wire provides an excellent reduction with good correction of neck shaft angle and good restoration of movements at the metcarpo-phalangeal and inter-phalangeal joints. Pre-bent K wire provides an efficient and economical modality of fixation in fracture neck of fifth metacarpal fractures.

Methods: All patients presenting with fracture neck of fifth metacarpal were managed by pre-bent K wire in antegrade fashion by a single surgeon using a single prebent K wire.

Results: All the fractures involved the dominant hand (16 right and 6 left). The mean duration of surgery was 24 mins. Intra operatively the mean no of X ray shoots were 12. At the end of the follow-up there was no significant difference in the TAM in the affected and the unaffected hand. The $p=0.17$. The mean DASH at the end of the follow up was 2.42. The mean fracture healing time was 45 days.

Conclusions: Boxers fracture is very common fracture type in young active adults. Conservative management is usually associated with shorting and angular deformities. Percutaneous fixation of the fracture with bent K wire placed in antegrade fashion provides good stability at the fracture site.

Keywords: Boxer's fracture, Metacarpal, Neck, Pre bent K wire

INTRODUCTION

Injuries to small bones of the hand are commonly encountered, resulting in fracture of metacarpal and phalanges. Among all metacarpal fractures, fracture of neck of fifth metacarpal is most common. It is also called "boxer's fracture" which account for about 36% of all metacarpal fractures.^{1,2} The incidence of boxer's fracture is about 20% of all hand injuries and the prevalence is more in young, active males.^{3,4} The most common mode of injury is an axial impact on a clenched fist. It is commonly observed in young individual with aggressive behaviors.

A bio mechanical study showed that a fracture angle of more than 45 degree produced significant muscle restriction that can limit movement of fifth digit but a fracture angle up to 30 degree is compatible with normal functions.⁵

There are many nonsurgical and surgical modalities which have been used to treat the displaced fractures of fifth metacarpal neck. The management depends on the severity of trauma and the degree of displacement. Displacement of the head in the direction of flexion tends to heal poorly as a result of the deforming force of intrinsic muscles.^{6,7} Both cosmetic disfiguration and

functional loss may occur in cases with inappropriate reduction and fixation

Surgery is recommended when clinical malrotation of fifth finger as noted on flexion and longitudinal shorting more than 3 mm. Several surgical techniques has been used such as antegrade intramedullary K-wire, retrograde intramedullary K-wire, retrograde cross pinning with k-wire, transverse pinning K-wire, external fixation, intraosseous wiring and plate fixation A.^{8,9}

Foucher et al, Kim and Kim et al suggested that antegrade intramedullary K-wire technique is reliable and safe modality or technique produces good fracture reduction and excellent ROM of the fifth finger for the patient with fifth metacarpal neck fractures.¹⁰⁻¹²

In our study we plan to assess the degree of angular correction and improvement in the finger movements that can be achieved while fixing the boxers fracture with a single intramedullary pre-bent K wire introduced in antegrade fashion.

METHODS

It was a prospective study conducted in the department of Orthopaedics, ESIC Medical College, Gulbarga after obtaining ethical committee clearance. The study duration was three years form June 2016 to July 2018. All patients presenting with fracture neck of fifth metacarpal were managed by the same technique and by a single surgeon using a single prebent K wire. Patient demographics including age, sex, occupation, handedness and other associated medical problems were collected. The mechanism of injury was noted and the side involved was clinically examined for rotational deformity. A series of 30 patients with fractures of the neck of the fifth metacarpal bone (boxer's fracture) were included in the study. Inclusion criteria were angulation greater than 45 degree versus the contralateral uninjured side when measured on a 25 degree-pronated (oblique view) on plain X-ray of both hands preoperatively. Open fracture, concomitant fractures, and children younger than 18 years were excluded. Articular fractures were not included in the study.

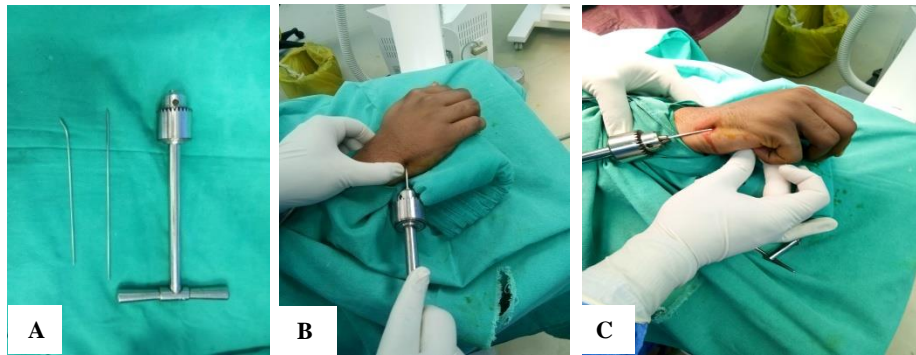


Figure 1: (A) T handle, 2.0 mm k wire for making entry point, 1.5 mm prebent K wire for intrmedullary fixation; (B) entry point being made under image intensifier; (C) fracture being reduced using the Jahss manoeuvre.

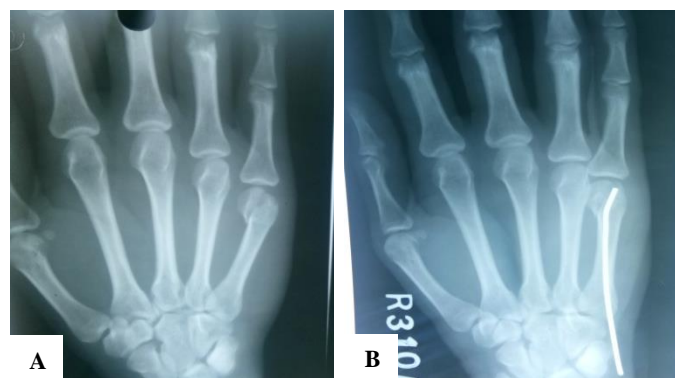

Figure 2: (A) Preoperative radiograph showing the angulation of the neck of the fifth metacarpal; (B) the angle being corrected by the bent k-wire introduced in antegrade manner.

Surgical technique

Informed consent was obtained from all patients after explaining the procedure. All the procedures were performed under wrist block. K wiring was done using T

handle and under image intensifier (Figure 1). The entry point was made at the base of the 5th metacarpal using a 2 mm k wire as a bone awl. A blunt tip 1.5 mm K-wire was bent to about 15 deg at one end. This wire was introduced through the entry point, into the proximal fragment. Jahss manoeuvre was used to get reduction of the fracture ends

and the wire was further advanced into the distal fragment.¹³ The wire was then rotated to achieve perfect head neck angle compared to the adjacent metacarpals. A ulnar gutter slab was applied in all patients with MCP

joint in 90 deg of flexion (Jones position). Time for procedure and stay time at hospital were documented. Patients received 2 doses of injectable antibiotics and were discharged on the second day.

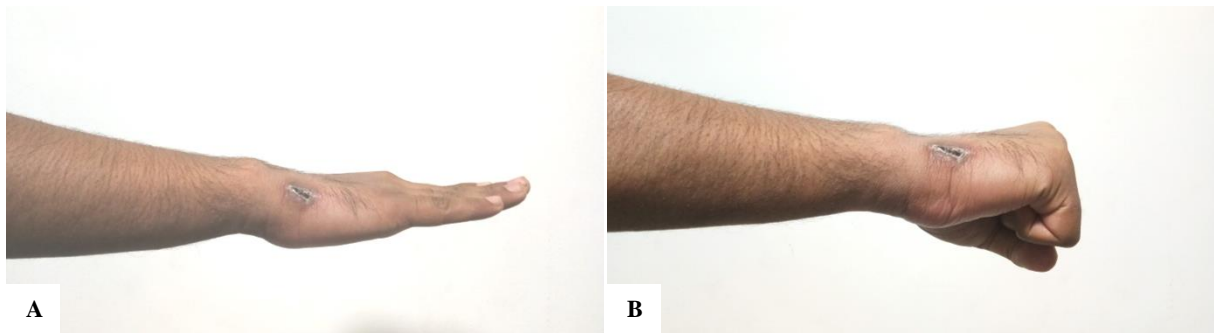


Figure 3 (A and B): Full TAM at the end of 3rd month.

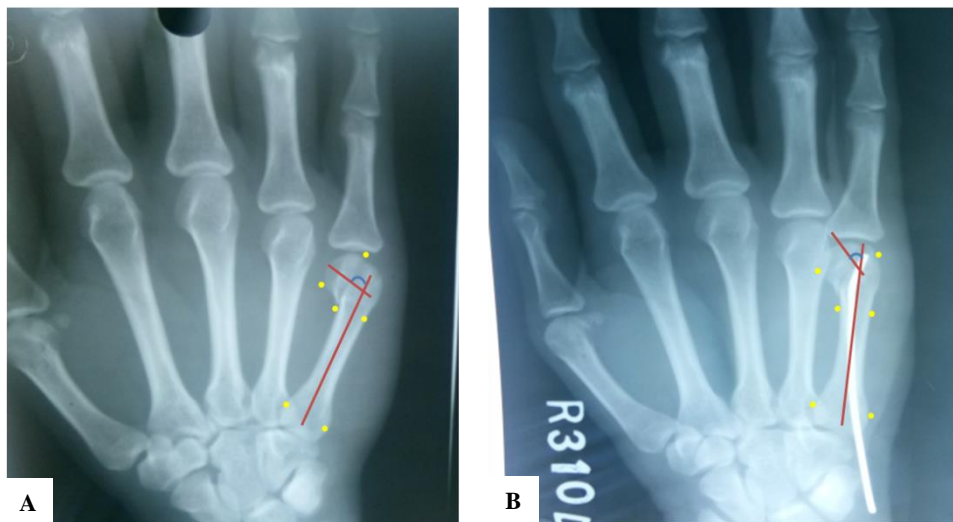

Figure 4: (A) Preoperative neck shaft angle– 110 deg; (B) postoperative neck shaft angle– 30 deg.

Follow up

Post operatively all the patients were assessed clinically and radiologically at 4 weeks, 8 weeks and 12 weeks (fig 2). At each follow up TAM (total active motion) and TPM (total passive motion) at the MCP and IP joints was assessed (Figure 3). Presence of any rotational deformity was documented. Antero-posterior (AP) and oblique X-rays were taken to assess the head neck angle. Preoperative and post-operative head neck angles were compared and the percentage of angular correction was assessed (Figure 4).

Statistical analysis

We have done all the statistical analysis using SPSS software version. Students T test was used as a test of significance to compare the improvement between the affected and the unaffected hand.

RESULTS

Twenty one patients were included in our study and the mean follow up period was 3months and the total study duration was of 3years. All the fractures involved the dominant hand (16 right and 6 left) (Table 1). All the surgeries were performed by a single surgeon and the mean duration of surgery was 24 mins. The mean no of X ray shoots intraoperatively were 12. The mean TAM of the affected hand at the last follow-up was recorded and was compared with that of the unaffected hand. We found that at the last follow up the mean TAM of the affected hand was 277 deg. At the end of the follow-up there was no significant difference in the TAM in the affected and the unaffected hand When compared with the affected hand there was no significant difference between the affected and the unaffected hand (p=0.17) (Table 2).

We also compared the Preoperative and the postoperative neck shaft angles. We found that there was a mean

improvement of 32.82 deg angle at the last follow up. DASH scores were also calculated.¹⁴ The mean DASH at the end of the follow-up was 2.42.

The mean fracture healing time was 45 days and the wire was removed after confirming fracture healing.

Table 1: Demographic details of the patients.

Characteristics	Values
Mean age (years)	34±2.2
Sex male/female	6:1
Right /left side	15/6

Table 2: TAM at the last follow up and its comparison with the unaffected hand (correction of the neck shaft angle and the percentage of improvement are also shown).

Sl no.	AM AH	TAM UAH	% improvement	Preop neck shaft angle	Post op neck shaft angle	% of improvement
1	270	275	98.18	65	25	38.46
2	255	260	98.07	60	18	30
3	300	305	98.36	68	16	23.52
4	290	290	100	70	20	28.57
5	278	282	98.58	55	16	29.09
6	295	300	98.33	52	22	42.30
7	278	282	98.58	64	20	31.25
8	270	275	98.18	58	24	41.37
9	260	265	98.11	65	15	23.07
10	300	305	98.36	60	20	33.33
11	278	282	98.58	60	18	30
12	251	255	98.43	55	24	43.63
13	280	280	100	65	15	23.07
14	277	285	97.19	58	19	32.75
15	260	265	98.11	62	23	37.09
16	280	278	100.71	55	18	32.72
17	265	270	98.14	66	20	30.30
18	292	300	97.33	52	24	46.15
19	272	275	98.90	56	25	44.64
20	285	290	98.27	68	16	23.52
21	280	284	98.59	56	19	33.92
Mean value	276.95 SD=13.91	281.09 SD=14.02	98.52 SD=0.82	60.47 SD=5.46	19.85 SD=3.33	32.82 SD=7.29

DISCUSSION

Fifth metacarpal fracture is very common. Most of the fractures are simple, closed and stable and are treated conservatively.^{1,2,4,6} If the fractures are not stabilized properly cosmetic and functional problems may occur.⁵ Closed reduction of displaced metacarpal neck fracture is reported to be difficult to achieve and impossible to retain in reduced position by non-operative methods. By closed means using plaster splints, three point fixation cannot be achieved.¹⁵⁻¹⁷ Green and Rowland mentioned that all the fractures of metacarpal neck are inherently unstable due to deforming muscle forces and volar comminution at the fracture site.^{18,19} Indications for operative treatment include mal-rotation, longitudinal shortening and excessive angulations of the head. Majority of surgeons agree that a shortening of the metacarpus by more than 3 mm and any rotation deformity is poorly tolerated and needs correction.

Open reduction and internal rigid fixation using plates has been recommended for unstable fractures.^{1,2} These may cause problems with fracture healing, soft tissue tethering, extensor tendon adhesions, and wound breakdown. Both antegrade and retrograde percutaneous pinning have been describe in literature. Kim et al conducted a study in which he compared antegrade vs retro grade pinning in displaced fractures.⁸ They found that antegrade pinning achieved better outcomes than patients in the retrograde group for all clinical parameters at 3 months postoperatively.

In our study we have used a bent k wire introduced in antegrade fashion to provide reduction of the fragment. We found that the bent k wire not only provides good reduction but also provides a stable fixation. There was no significant difference between the affected and the unaffected hand with respect to the TAM at the end of 3 months. There was mean angular correction of 32.82%.

The mean DASH score at the final follow up was 2.42 and the average healing time was 6weeks

CONCLUSION

Boxers fracture is a very common fracture type in young active adults. Conservative management is usually associated with shortening and angular deformities. Percutaneous fixation of the fracture with bent K wire placed in antegrade fashion provides good stability at the fracture site. The bent nature of the wire helps in correction of rotation and angular deformities. This is a relatively easy technique with good postoperative results and has an short learning curve.

Funding: No funding sources

Conflict of interest: None declared

Ethical approval: The study was approved by the institutional ethics committee

REFERENCES

1. Mohammed R, Farook MZ, Newman K. Percutaneous elastic intramedullary nailing of metacarpal fractures: surgical technique and clinical results study. *J Orthop Surg Res.* 2011;6:37.
2. Yammine K, Harvey A. Antegrade intramedullary nailing for fifth metacarpal neck fractures: a systematic review and metaanalysis. *Eur J Orthop Surg Traumatol.* 2014;24:273–8.
3. Hunter JM, Cowen NJ. Fifth metacarpal fractures in a compensation clinic population: a report on one hundred and thirty-three cases. *J Bone Joint Surg Am.* 1970;52:1159–65.
4. Gudmundsen TE, Borgen L. Fractures of the fifth metacarpal. *Acta Radiol.* 2009;50(3):296-300.
5. Ali A, Hamman J, Mass DP. The biomechanical effects of angulated boxer's fractures. *J Hand Surg Am.* 1999;24:835–44.
6. Cepni SK, Aykut S, Bekmezci T, Kilic A. A minimally invasive fixation technique for selected patients with fifth metacarpal neck fracture. *Injury.* 2016;47(6):1270-5.
7. Diaz-Garcia R, Waljee JF. Current management of metacarpal fractures. *Hand Clin.* 2013;29:507-18.
8. Kim JK, Kim DJ. Antegrade intramedullary pinning versus retrograde intramedullary pinning for displaced fifth metacarpal neck fractures. *Clin Orthop Relat Res.* 2015;473(5):1747-54.
9. Wong TC, Ip FK, Yeung SH. Comparison between percutaneous transverse fixation and intramedullary K-wires in treating closed fractures of the metacarpal neck of the little finger. *J Hand Surg Br.* 2006;31:61-5.
10. Facca S, Ramdhian R, Pelissier A, Diaconu M, Liverneaux P. Fifth metacarpal neck fracture fixation: locking plate versus K-wire? *Orthop Traumatol Surg Res.* 2010;96:506-12.
11. Fujitani R, Omokawa S, Shigematsu K, Tanaka Y. Comparison of the intramedullary nail and low-profile plate for unstable metacarpal neck fractures. *J Orthop Sci.* 2012;17:450-6.
12. Schadel-Hopfner M, Wild M, Windolf J, Linhart W. Antegrade intramedullary splinting or percutaneous retrograde crossed pinning for displaced neck fractures of the fifth metacarpal? *Arch Orthop Trauma Surg.* 2007;127:435–40.
13. Jahss S. Fractures of the metacarpals: a new method of reduction and immobilization. *J Bone Joint Surg Am.* 1938;20:178–86.
14. Hudak PL, Amadio PC, Bombardier C. Development of an upper extremity outcome measure: the DASH (disabilities of the arm, shoulder and hand) [corrected]. The Upper Extremity Collaborative Group (UECG). *Am J Ind Med.* 1996;29(6):602-8.
15. Braakman M. Is anatomical reduction of fractures of the fourth and fifth metacarpals useful? *Acta Orthopaedica Belgica.* 1997;63(2):106-9.
16. Eichenholtz SN, Yonkers NY, Rizzo PC. Fracture of the neck of the fifth metacarpal bone. Is over-treatment justified? *J Am Med Association.* 1961;178:425-6.
17. Foucher G. "Bouquet" osteosynthesis in metacarpal neck fractures: a series of 66 patients. *J Hand Surg.* 1995;20:86-90.
18. Hall RF Jr. Treatment of metacarpal and phalangeal fractures in noncompliant patients. *Clin Orthop Related Res.* 1987;214:31-6.
19. Leung YL, Beredjikian PK, Monaghan BA, Bozentka DJ. Radiographic Assessment of Small Finger Metacarpal Neck Fractures. *J Hand Surg.* 2002;27:443-8.

Cite this article as: Sadiq M, Hussain SA. Management of boxers fracture with single antegrade bent K-wire. *Int J Res Orthop* 2019;5:398-402.